

# 43 Stature Lengthening: Skeletal Dysplasia

John E. Herzenberg and Dror Paley

*Rubin Institute for Advanced Orthopedics, The International Center for Limb Lengthening,  
Sinai Hospital, Baltimore, Maryland, U.S.A.*

## INTRODUCTION

This chapter will discuss our latest methods of management of lower and upper limb deformities and short stature in patients with achondroplasia and hypochondroplasia. These represent the vast bulk of skeletal dysplasias. Other skeletal dysplasias are less common, and we tend to focus more on limb realignment rather than lengthening for those other conditions.

Children with achondroplasia typically present for orthopedic evaluation after already having been diagnosed by a geneticist. Achondroplasia accounts for about 75% of all dwarfism. However, it is nonetheless a rare condition, affecting 1/50,000 children. Therefore, most achondroplastic children will grow up in communities without any peers sharing the same diagnosis. The gene for achondroplasia is a point mutation on the fibroblast growth factor receptor-3 gene, located on the short arm of the fourth chromosome. Achondroplasia is transmitted as an autosomal dominant gene, with the double dose being lethal. Still, 80% of cases are spontaneous mutations, and these patients are born of normal stature parents. Hypochondroplasia is genetically similar to achondroplasia, with the same gene involved, but with a slightly different nucleotide change. Hypochondroplasia is phenotypically a much milder form of dwarfism. In this chapter, we focus on the more clinically challenging problem of achondroplasia because hypochondroplasia represents clinically less need for deformity correction and the total amount of lengthening is less.

In addition to the obvious limb deformities of short stature and bowing, children with achondroplasia also have frontal bossing, midface hypoplasia, thoracolumbar kyphosis, delayed developmental milestones, and spinal stenosis. They may suffer from foramen magnum stenosis and hydrocephalus. Therefore, prior to undergoing limb reconstruction surgery, patients with achondroplasia should be evaluated for possible spinal cord compression, hyperreflexia, clonus, sleep apnea, and thoracolumbar kyphosis.

Achondroplastic dwarfism presents with a rhizomelic disproportion, short stature, and several characteristic limb deformities. The primary defect is in endochondral ossification, which affects primarily the central region of the growth plate while sparing the peripheral ring of the growth plate. Therefore, the larger the proportion of central growth plate to peripheral growth plate, the greater the growth inhibition. According to the theory of Ponseti, the distal femur, which has the largest growth plate, is affected the most. This accounts for the rhizomelia of the lower limb. Similarly, the proximal humerus has the largest growth plate in the upper limb, so it is most affected, which leads to upper limb rhizomelia too. The fibula has a relatively small growth plate with a much higher ratio of peripheral to central growth cartilage compared with the adjacent tibia. The growth of the tibia is, therefore, more affected than that of the fibula, leading to relative fibular overgrowth. Overgrowth of the fibula causes developmental varus of the proximal and distal joint lines of the tibia, lateral collateral ligament laxity, and consequently dynamic varus with a lateral thrust during the single-leg stance of gait, and developmental internal tibial torsion. In the proximal femur, the femoral neck has a larger growth plate than the greater trochanteric apophysis. This leads to trochanteric overgrowth, a vara, and a short femoral neck.

In the upper extremity, flexion deformity of the elbow is common. This is partly due posterior bowing of the ulna, due to greater stunting of growth of the larger distal radius growth plate than the relatively small distal ulnar physis. In more severe cases, the radial head dislocates to accommodate the slower-growing ulna. The spine is relatively spared inhibition because the vertebrae grow in height from the apophyseal growth plate. This is a peripheral growth plate structure more than a central growth plate. The acetabulum is more anteriorly located in achondroplasts possibly due to differential growth of the three separate limbs of the triradiate cartilage. Because the pelvis is tilted forward and because the iliac side is more inhibited, the acetabulum becomes relatively posterior, shifting the center of the femoral head back. This leads to a flexion deformity of the hip, which is compensated by hyperlordosis of the lumbar spine.

## CLINICAL EVALUATION

Prior to lengthening, children with achondroplasia should undergo a thorough orthopedic and neurologic evaluation with special emphasis on joint range of motion (ROM)/stability, including hip flexion contracture, ankle contracture, knee ROM, and elbow ROM. One should also assess gait and look for signs of neurologic involvement. Radiographs should include standing views of both legs (anteroposterior and lateral) and ones of the spine. The following table summarizes the clinical signs associated with these deformities:

Deformity	Clinical Manifestation
Varus distal tibia	Varus foot
Varus proximal tibia	Genu varum
Overtgrowth of proximal fibula	Lateral thrust (lateral knee instability)
Internal tibial torsion	Intoeing gait
Overtgrown trochanter	Waddling gait
Hip flexion deformity	Hyperlordosis
Bowing of ulna/dislocation radial head	Elbow flexion deformity
Flexion deformity of distal humerus	Elbow flexion deformity
Rhizomelia	Disproportionate short stature

## STATURE IN ACHONDROPLASIA

The stature of achondroplastic dwarfs falls significantly below the standard growth charts for children. Therefore, special growth charts have been developed to follow the growth of these children. The average adult height for achondroplastic men is 131 cm and for women is 125 cm. The range (2 SD) of height for achondroplastic men at maturity is 117 to 144 cm and for women is 113 to 157 cm. In comparison, the low normal end of height at maturity for men without achondroplasia is 160 cm and for women is 151 cm. Tall parental height is associated with relatively taller height in achondroplastic offspring. The short stature of achondroplastic patients is not simply due to growth at a different rate than in normal children. These children have a completely different growth pattern. The height multipliers for achondroplastic children are completely different than for normal children (Tables 1 and 2).

## GOALS OF LENGTHENING SURGERY FOR ACHONDROPLASIA

The goals of surgery are to correct upper and lower limb deformities while at the same time increasing stature to the low end of the normal height spectrum. This theoretically requires leg lengthening of about 30 cm (men) or 25 cm (women) for the average patient with achondroplasia. Lengthening of the lower extremities can be 10 to 15 cm per session, so the total number of leg-lengthening procedures required to achieve these goals is two to three leg-lengthening sessions. The humeri are lengthened separately. Deformity correction of the

**Table 1** Height Multiplier for Achondroplastic Boys

Age (yr)	Average Multiplier
0	2.848
1	2.107
2	1.798
3	1.679
4	1.579
5	1.501
6	1.430
7	1.366
8	1.318
9	1.270
10	1.221
11	1.181
12	1.145
13	1.105
14	1.079
15	1.054
16	1.032
17	1.018
18	1.000

lower limbs for achondroplasia is a well-accepted procedure. Lengthening for stature is still somewhat controversial. This controversy will be discussed in detail below.

## CLASSIFICATION AND TREATMENT STRATEGIES FOR LENGTHENING IN ACHONDROPLASIA

### Strategy for Juveniles (Young Children)

#### *First Lengthening Between Ages 7 and 10 Years*

Simultaneously lengthen both femora and both tibiae a total of 10 cm each (5-6 cm in each femur and 4-5 cm in each tibia) (Fig. 1A-E).

Correct bowlegs and internal tibial torsion.

Average external fixation treatment time is five months.

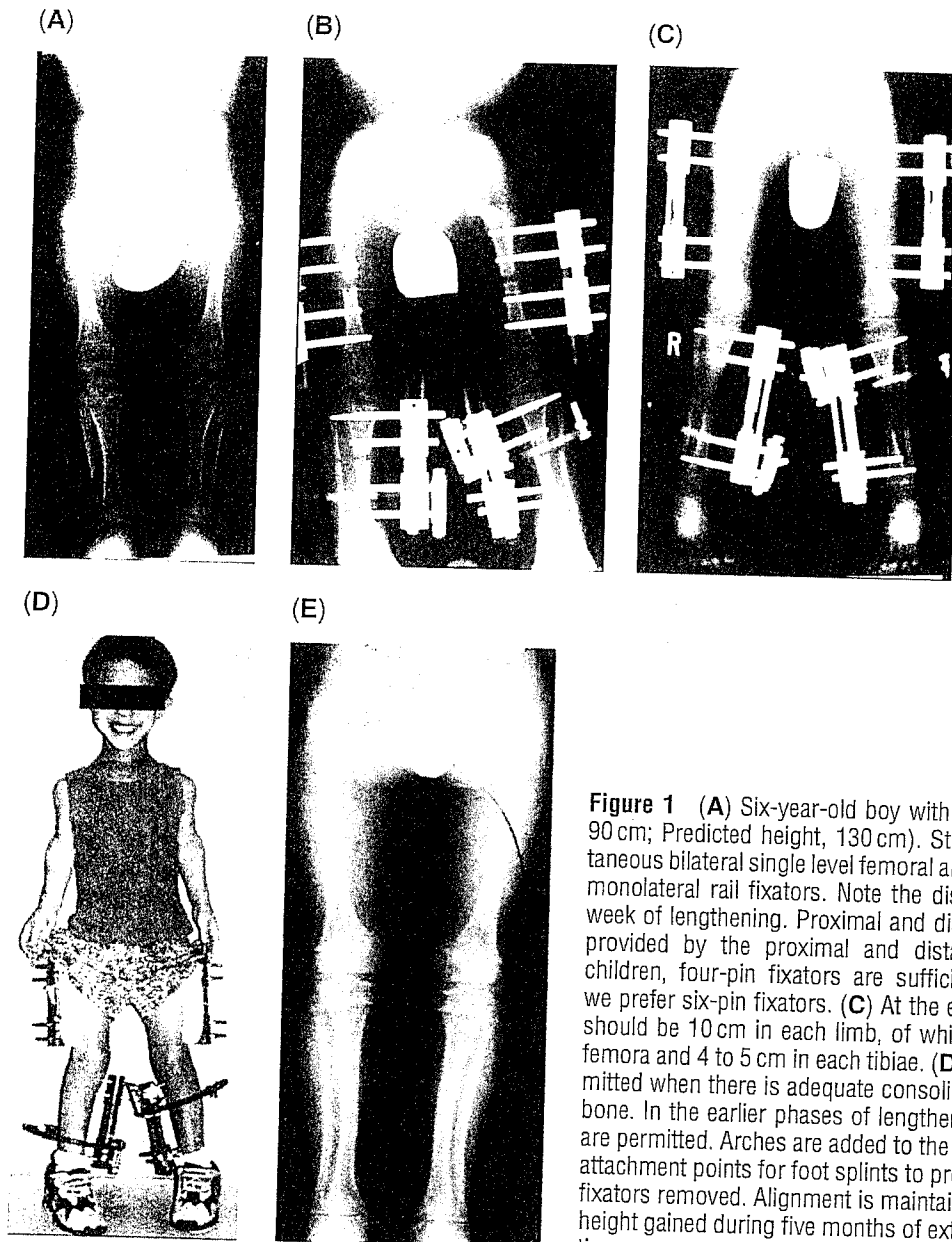
#### *Second, Third, and Fourth Lengthenings as in the Strategy for Adolescents*

Total increase in lower limb length is 30 to 35 cm.

Total increase in upper limb length is 10 cm.

**Table 2** Height Multiplier for Achondroplastic Girls

Age (yr)	Average Multiplier
0	2.655
1	1.943
2	1.744
3	1.632
4	1.535
5	1.461
6	1.400
7	1.343
8	1.274
9	1.222
10	1.170
11	1.130
12	1.098
13	1.066
14	1.042
15	1.023
16	1.009
17	1.000



**Figure 1** (A) Six-year-old boy with achondroplasia (Height, 90 cm; Predicted height, 130 cm). Straight limbs. (B) Simultaneous bilateral single level femoral and tibial lengthening with monolateral rail fixators. Note the distraction gaps after one week of lengthening. Proximal and distal fibular fixation were provided by the proximal and distal tibial pins. In small children, four-pin fixators are sufficient. In larger children, we prefer six-pin fixators. (C) At the end of lengthening. Goal should be 10 cm in each limb, of which 5 to 6 cm is in each femora and 4 to 5 cm in each tibiae. (D) Weight bearing is permitted when there is adequate consolidation of the regenerate bone. In the earlier phases of lengthening, standing transfers are permitted. Arches are added to the tibial fixators to provide attachment points for foot splints to prevent equinus. (E) After fixators removed. Alignment is maintained. Ten centimeters of height gained during five months of external fixation treatment time.

### Strategy for Adolescents

#### First Lengthening at About 13 Years of Age

##### Option 1

Double-level tibial lengthening; if varus proximal tibia and varus distal tibia, then perform double-level bilateral tibial lengthening 10 to 15 cm with deformity correction (Fig. 2).

Typically, more length is achieved in the proximal osteotomy.

Correct the varus deformity of the proximal tibia through proximal osteotomy.

Correct the varus deformity of the distal tibia through the distal osteotomy.

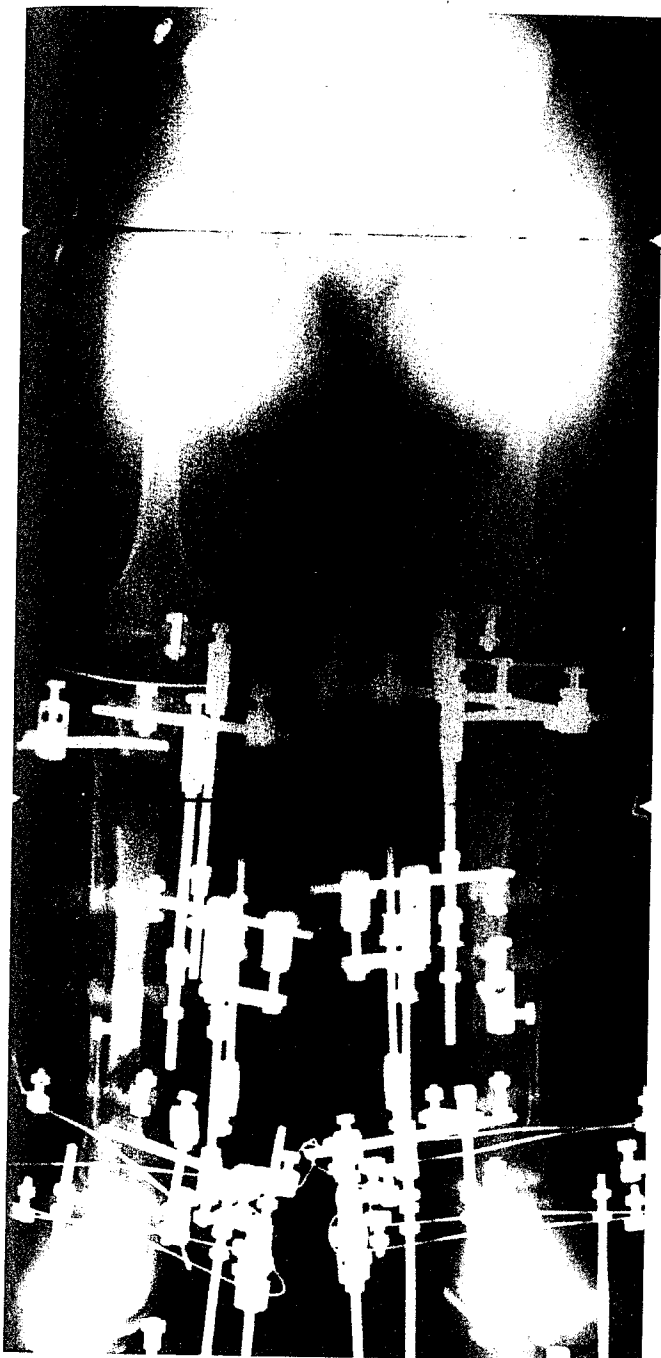
Tighten the lateral collateral ligament during the final stages of the lengthening.

Average external fixation treatment time is six to nine months.

##### Option 2

Bilateral simultaneous femoral and tibial lengthening; if no significant distal tibial varus, then lengthen both femora and both tibiae 10 to 15 cm (5-8 cm in each femur and 5-7 cm in each tibia) (Fig. 3A-C).

Average external fixation treatment time is five to seven months.



**Figure 2** Sixteen-year-old achondroplastic dwarf underwent bilateral simultaneous double level tibial lengthening and straightening. At the end of lengthening, the patient had 6 cm of new bone in proximal osteotomy and 5 cm of new bone in distal osteotomy.

### ***Second Lengthening at Age 14 Years***

Lengthen both humeri 8 to 10 cm (Fig. 4A–E).

Correct flexion deformity of elbows if significant ( $>30^\circ$ ).

Average external fixation treatment time is six to eight months.

### ***Third Lengthening Between Ages 15 and 16 Years***

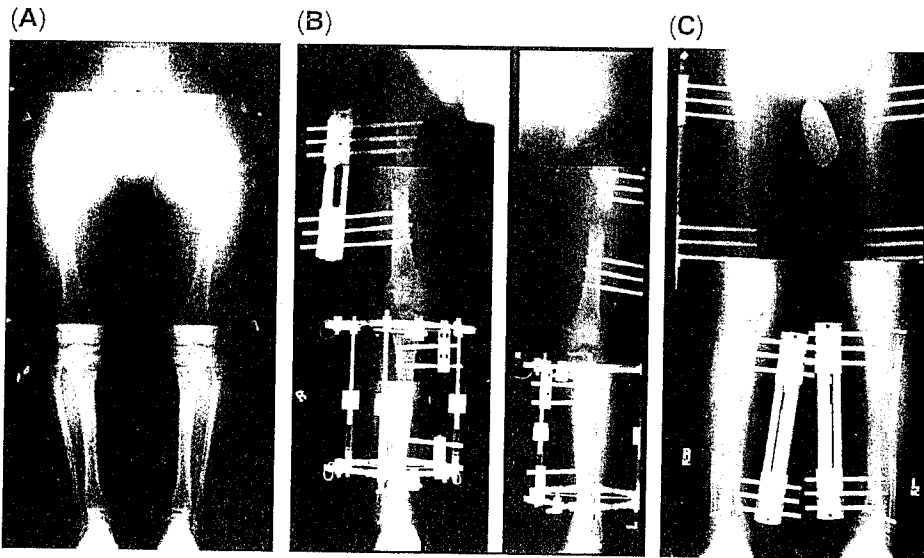
#### ***Option 1***

Lengthen both femora 10 cm through proximal osteotomy (Fig. 5A–C).

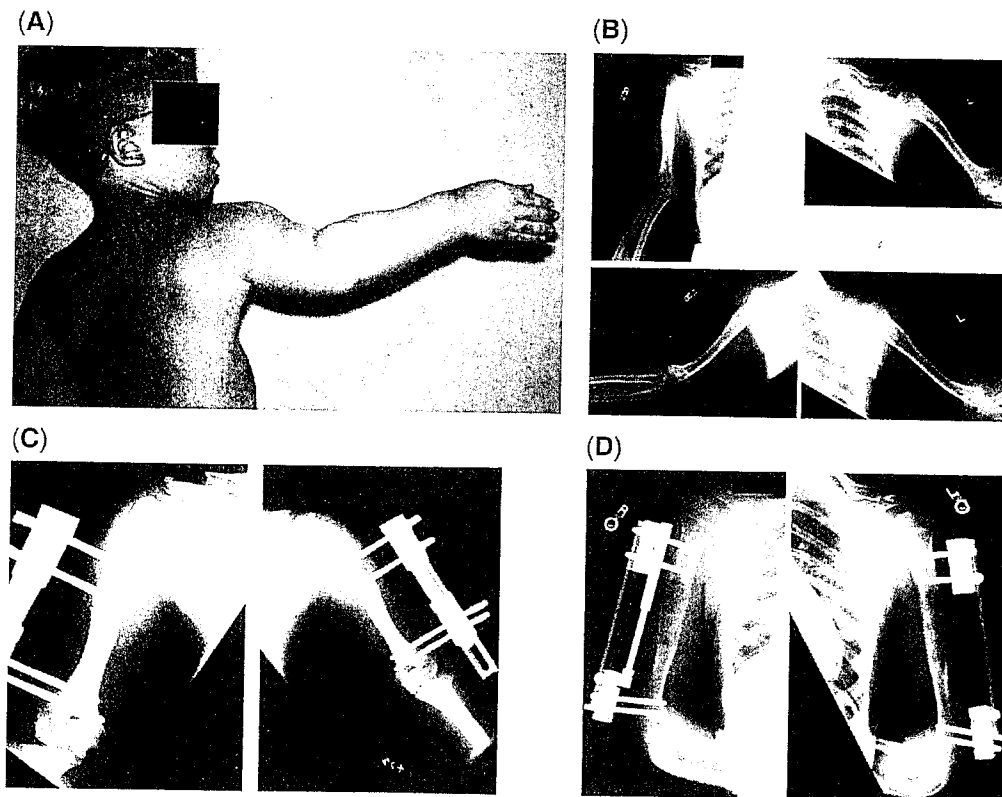
Correct flexion deformity of both hips (this reduces the lumbar hyperlordosis).

Correct varus deformity of both hips.

Average external fixation treatment time is 10 to 12 months.



**Figure 3** (A) Eleven-year-old hypochondroplastic girl underwent bilateral simultaneous femoral and tibial lengthening. No malalignment was observed preoperatively. (B) Six-pin monolateral rail fixators were applied to the femora and spatial ring fixators were applied to the tibiae. Initial lengthening in tibiae is with spatial rings and Ilizarov graduated telescopic rods. At the end of lengthening, the spatial struts may be inserted for correction of any residual axis deviation. (C) Eleven-year-old achondroplastic boy underwent an aggressive bilateral simultaneous femoral and tibial lengthening to achieve 7.5 cm in each tibia and 8 cm in each femur. Monolateral fixators were used on both femora and tibiae.



**Figure 4** (A) Rhizomelic shortening is characteristic of achondroplasia. The humerus is disproportionately shorter than the forearm. The elbow lacks full extension. (B) Preoperative radiographs of a 16-year-old achondroplastic boy who underwent bilateral humeral lengthening. (C) Bilateral monolateral four-pin fixators applied. (D) Anteroposterior view of both humeri at the end of consolidation phase. About 8 cm of new bone has been achieved. (E) Fracture at the host-regenerate bone junction on the right side occurred from a fall one month postremoval of fixators. Intraoperative sequence of fracture reduction, reaming with flexible hand held reamer, and stabilization with Rush pin.

(E)

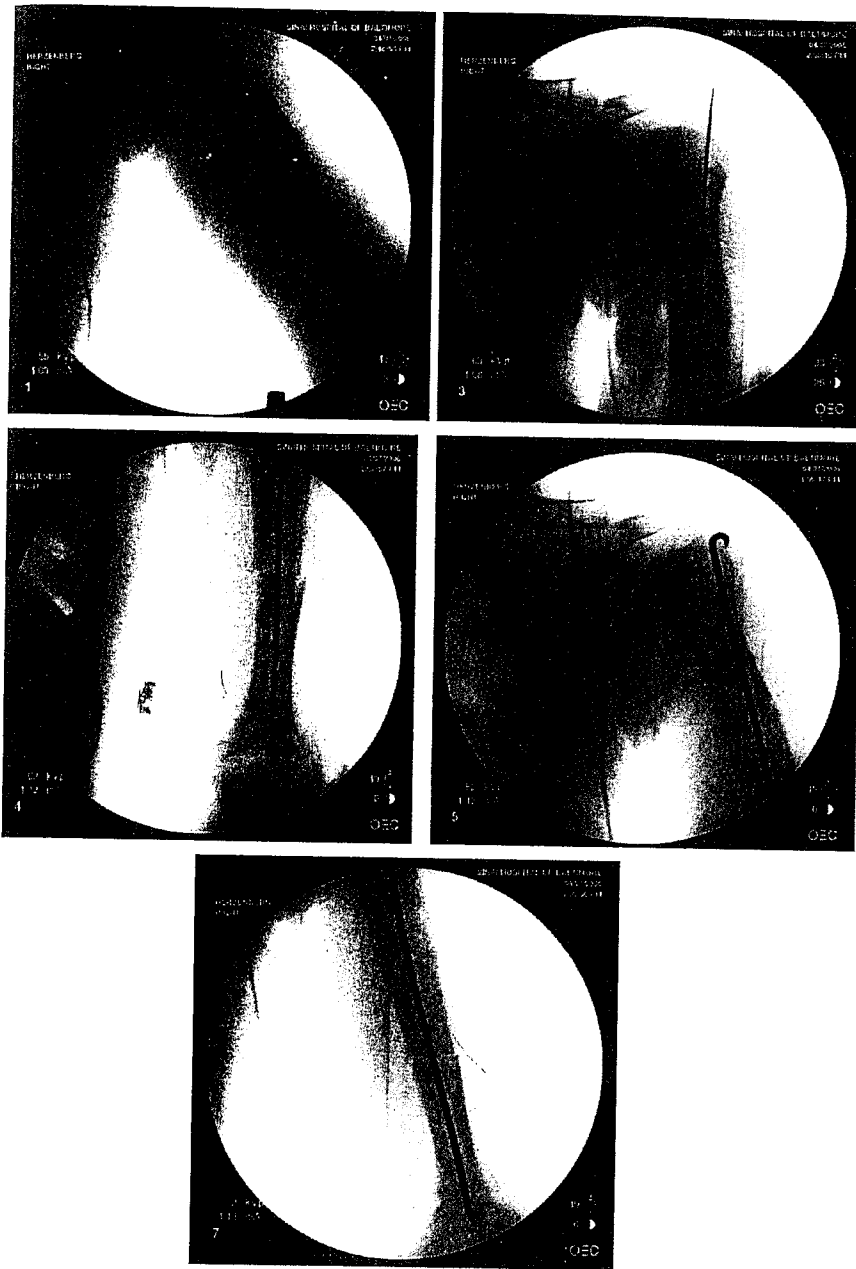


Figure 4 (Continued)

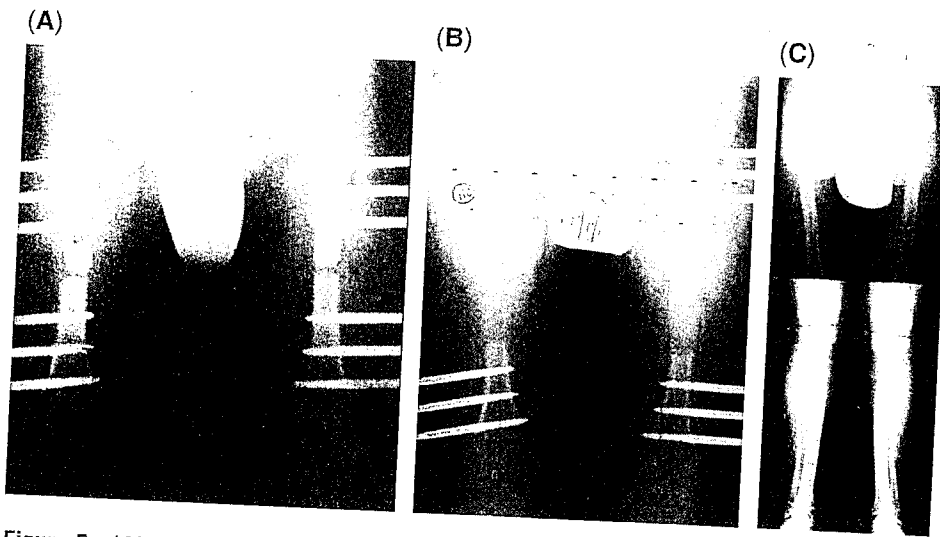
#### Option 2

- Or again simultaneously lengthen both femora and tibiae for a total of 10 to 15 cm.
- Correct flexion deformity of both hips to reduce lumbar hyperlordosis.
- Correct any distal femoral varus or valgus.
- Correct any residual tibial deformity.
- Average external fixation treatment time is five to seven months.

#### Fourth Lengthening at Age 17 to 18 Years

If needed, final lengthening of the femora, preferably with intramedullary techniques (Fig. 6A–B).

By lengthening the arms during the period of time between the two lower-limb lengthenings, the legs get a well-needed break from lengthening. The minimal time between lengthenings is generally at least 6 to 12 months after the device is removed.



**Figure 5** (A) Bilateral femoral lengthening with monolateral rail fixators. Six 6-mm pins are needed in adolescents to provide sufficient stability. (B) After 10 cm lengthening. Limited four-point gait is allowed in consolidation phase. (C) After external fixator removal. The femora are well aligned. Residual valgus is present in the tibiae, which was later corrected during a second tibial lengthening. Note the resected fibulae. This had been done as a youth to prevent the tibiae from growing into varus (Kopits procedure).

During bilateral tibial lengthenings, the patient is able to weight bear using a walker, crutches, or canes if using circular external fixators. Longer trips are by wheelchair. During bilateral simultaneous femoral plus tibial or bilateral femoral lengthenings, the patient is not permitted to walk on monolateral fixators during the lengthening phase. Weight bearing is allowed during the latter half of the consolidation phase. Standing is allowed for transfer only prior to that. Ambulation is by wheelchair only during the lengthening phase. During bilateral humeral lengthening, there is almost no restriction on activities.

The advantage of repeating simultaneous bilateral femoral and tibial lengthenings is that the total external fixation treatment time is reduced significantly. Furthermore, this method enables the maximum stature gain in the least time. For example, bilateral 10 cm femoral lengthenings take 10 months of external fixation time, while bilateral femoral and tibial lengthenings of 5 cm each for a total of 10 cm take only five months. The disadvantage of bilateral simultaneous femoral and tibial lengthenings is the increased nursing care and physical therapy involved.

## SURGICAL TECHNIQUES

### Bilateral Simultaneous Femoral and Tibial Lengthening

This is a lengthy procedure, and we often work with two teams sequentially. Start by performing the necessary soft-tissue releases under tourniquet control. For the first lengthening, there may be no need for soft-tissue releases. For the second lengthening, it may be advisable to lengthen the fascia lata, rectus femoris muscle, and gastrocnemius-soleus muscle (Fig. 7A-D).

#### Fixators

Use two LRS rail systems ( Orthofix, McKinney, TX, USA ) for the femora and two Taylor Spatial Frames (TSF) (Smith & Nephew, Memphis, TN, USA) or LRS rail system for the tibiae. Typically, the goal is length, so the femoral fixators may be applied parallel to the mechanical axis (Fig. 8). After placing the six pins, check knee ROM and consider fascia lata resection or sectioning, either percutaneously around the pin sites or through an open incision just anterior and distal to the distal pin cluster (Fig. 7D). For the tibial lengthening, either use a six-pin LRS rail system or a two-ring TSF. Either way, it is important to fix the fibula proximally and distally. Consider an anterior compartment fasciotomy. Pain can be difficult to judge postoperatively and fasciotomy eliminates the possibility of compartment syndrome. Always apply splints to the feet, suspended by Velcro straps attached to the tibial fixator.

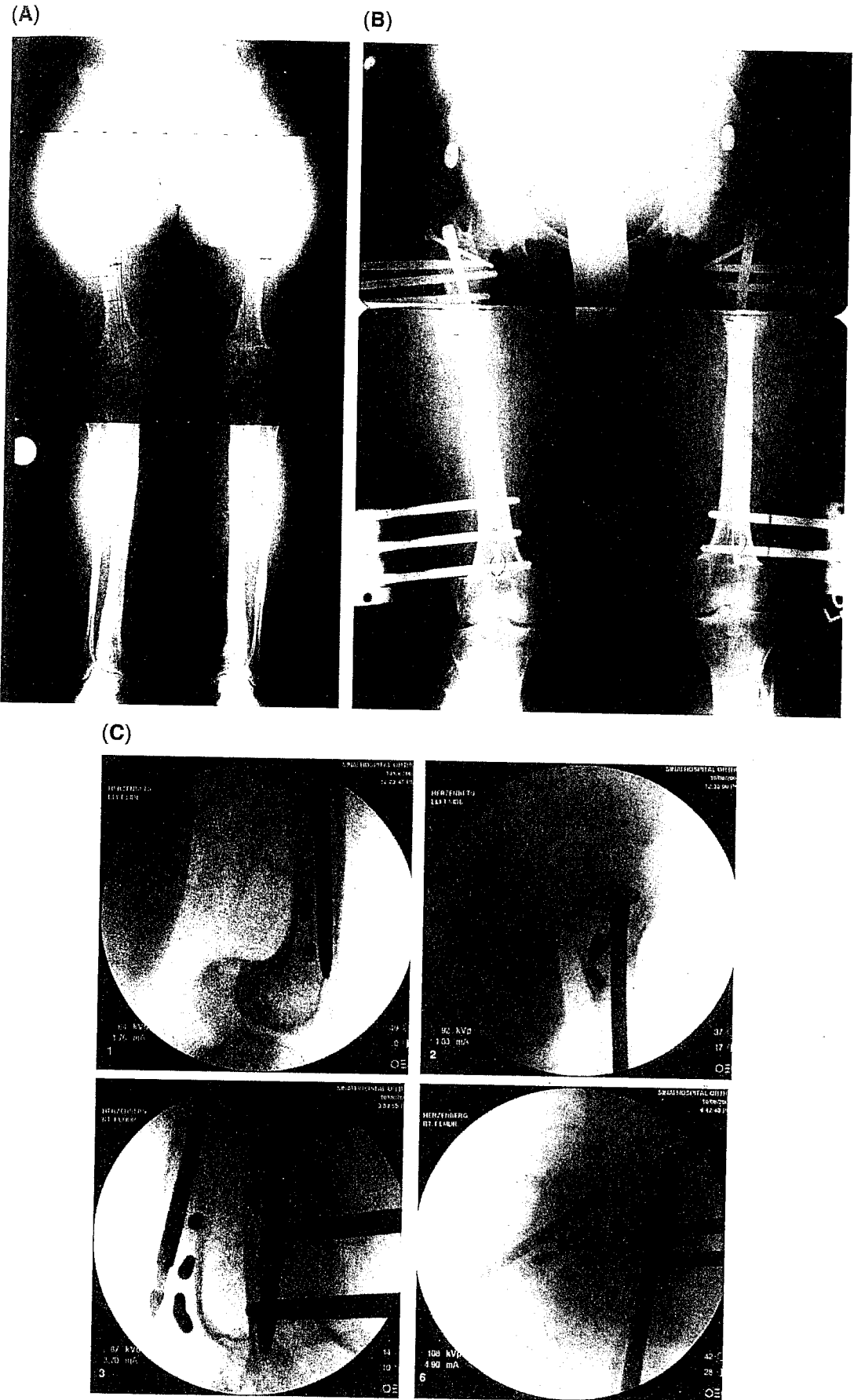
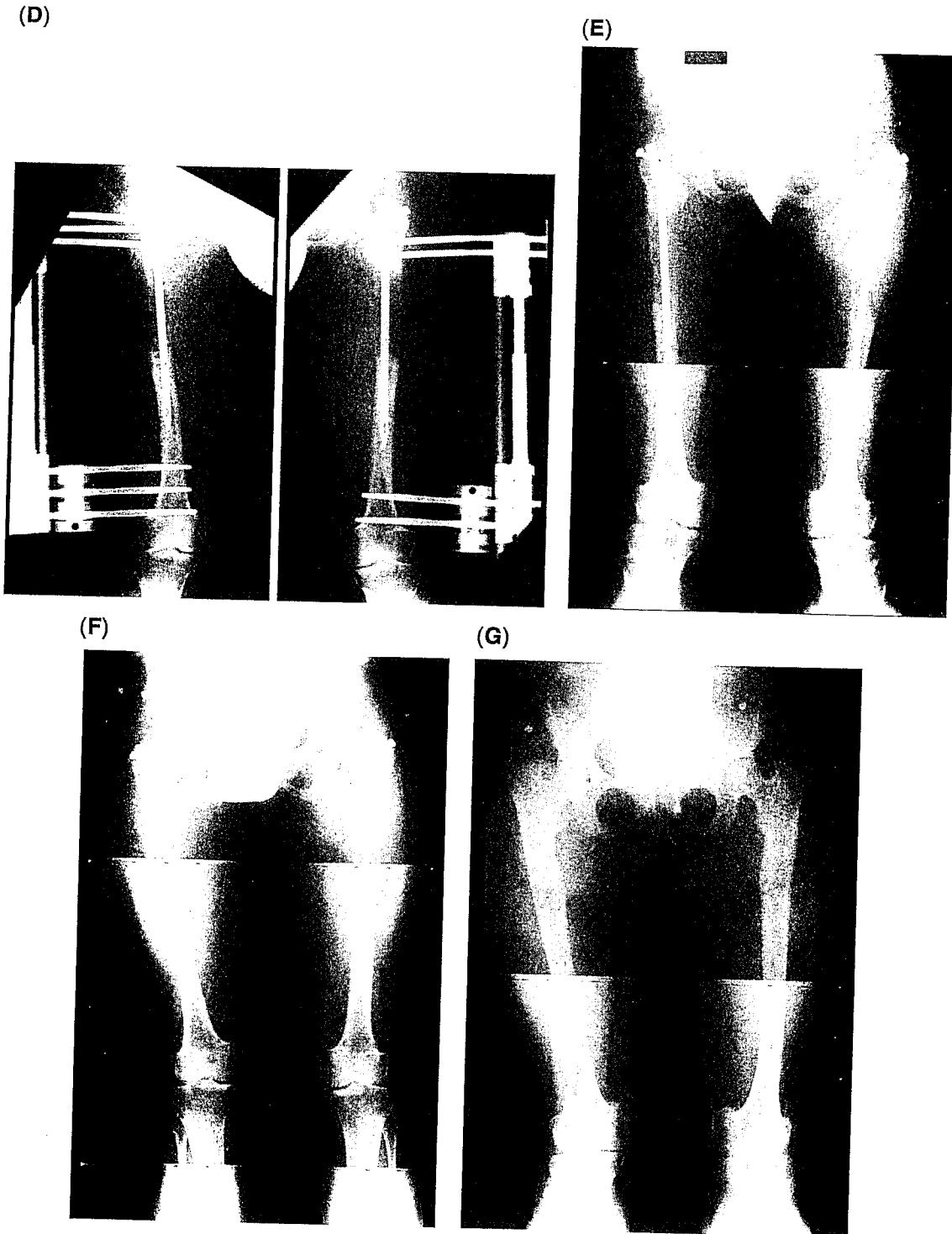
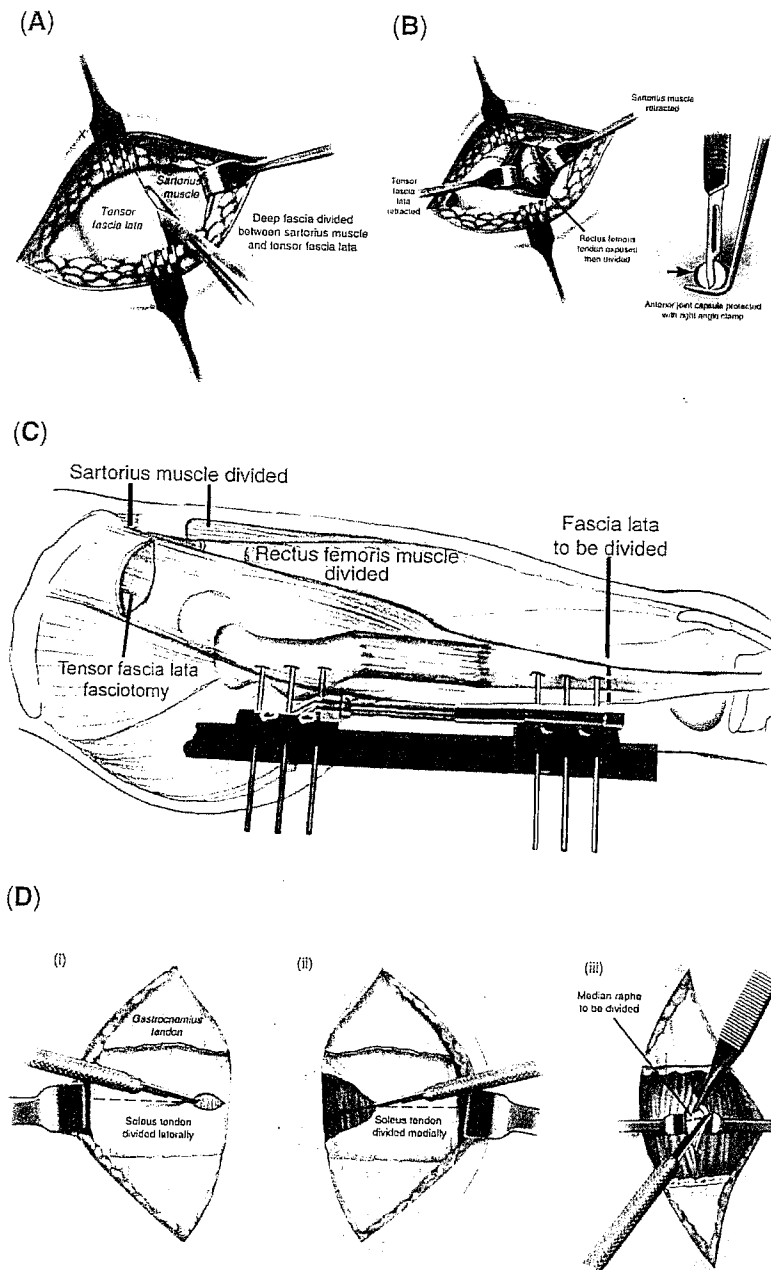


Figure 6 (Caption on next page)



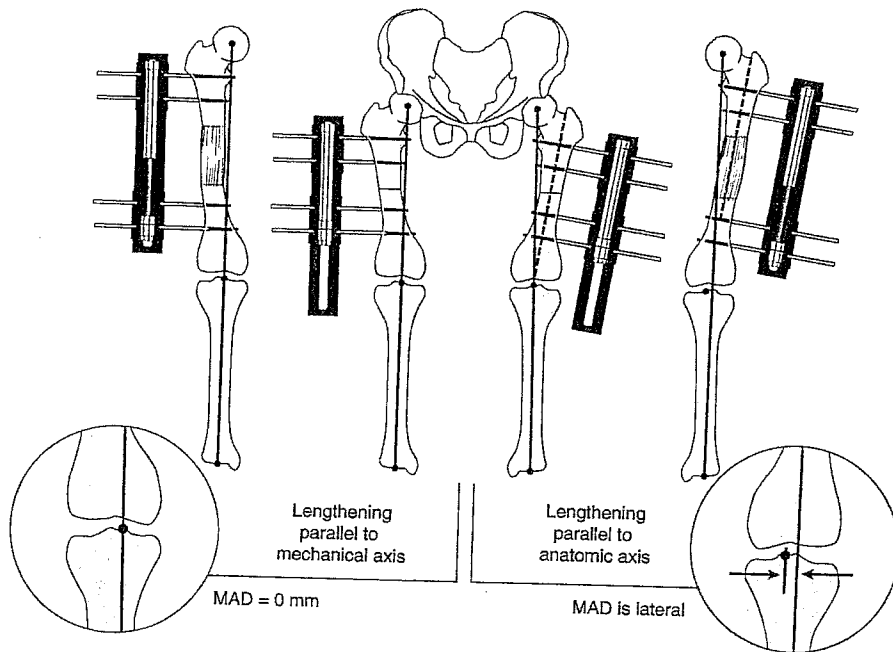
**Figure 6** (Continued from previous page) (A) Young achondroplastic adult after healing of bilateral double level tibial lengthenings. (Same patient as in Fig. 2). (B) Bilateral femoral lengthenings over nails. Eight-millimeter humeral nails were used due to the small canal size. On the right side, a six-pin monorail device was used for distraction. The left side distracted well with only four pins. (C) Intraoperative fluoroscopic images showing the pin placement. The external fixation pins must not have contact with the intramedullary nail. (D) Anteroposterior (AP) view of right and left femur at the end of lengthening. Nine centimeters achieved. (E) Two weeks after insertion of distal locking screws. (F) Three months after fixator removal, the regenerate bone is solid and hypertrophied. (G) AP view of both femora following removal of rods.



**Figure 7** (A) Surgical approach for the proximal soft tissue release of the rectus femoris tendon. The fascia over the tensor fascia lata (TFL) and sartorius muscle should also be released. (B) Deep dissection for the proximal soft tissue release of the rectus femoris tendon. (C) In addition to releasing the proximal tendon muscle of the rectus femoris, the fascial membrane over the TFL and sartorius muscle is also incised. Distally, the fascia lata is divided through a separate incision near the distal pin cluster. (D) Vulpius recession of the gastrocnemius-soleus muscle (i) dividing the lateral edge of the tendon, (ii) dividing the medial edge of the tendon, and (iii) dividing the central portion and the median raphe. *Source:* Panel (D) reprinted from Lamm BM, Paley D, Herzenberg JE. Gastrocnemius soleus recession: a simpler, more limited approach. *J Am Podiatr Med Assoc* 2005; 95(1):18–25.


### Bilateral Double-Level Tibial Lengthening

This is typically indicated when there is upper and lower tibial varus deformities. Begin by cutting the fibula and passing the Gigli saw at the proximal metaphyseal level. Distally, the osteotomy may be either diaphyseal or supramalleolar (metaphyseal). The Gigli saw is appropriate for metaphyseal levels but not diaphyseal levels. The very distal Gigli cut can be around both the tibia and fibula together. We recommend tibiofibular stabilization proximally and distally with a 4.5-mm solid bone screw (Fig. 9). This is accomplished by first drilling 1.5-mm wires from the head of the fibula into the tibia proximally and from the distal metaphysis of the fibula



**Figure 8** In the situation where there is no preoperative deformity, the monolateral fixator should be aligned with the mechanical axis, not the anatomic axis. Lengthening along the anatomic axis may induce valgus mechanical axis deviation.

distally. Check the position on lateral image intensification to prove that the fibula is captured and then ream over the wires with a 3.2-mm cannulated drill. The proximal screw may be deliberately left long, "outside" the skin medially, so that it can be easily removed toward the end of distraction. This allows the fibula to descend as the lengthening continues, thus tightening the lateral collateral ligament, if lax preoperatively. Only one fibular osteotomy is necessary. Use a three-ring external fixator such as the Ilizarov or TSF. The proximal ring is parallel to the knee, the distal ring is parallel to the ankle, and the middle ring is perpendicular to the diaphysis. There may not be room for TSF struts on a very short tibia. In such cases, it is possible to use TSF rings that are connected with regular Ilizarov hinges and rods. With some careful intraoperative planning, the half-pin fixation can be planned to allow later conversion to TSF struts in order to better correct rotational deformities and other unexpected axial deviations that



**Figure 9** Hypochondroplastic dwarf undergoing bilateral tibial and femoral lengthenings. Tibiofibular stabilization with proximal and distal 4.5-mm solid bone screws. The distal screw should slant upwards to resist the upward pull of the fibula.

may occur during lengthening. Once the length has been achieved, there is more room between the rings to accommodate the TSF struts, so they can be added in the out-patient clinic setting to fine-tune the correction. Vulpius gastrocnemius-soleus recession is recommended for all double-level lengthenings. The hindfoot should be included in the frame by extending the distal ring to the foot for calcaneal fixation. The two tibial osteotomies are made with a Gigli saw if in the wide metaphysis and with an osteotome and drills if made through the diaphysis only. The osteotomies are lengthened at 0 to 75 mm per day at each level. Typically, bone formation is better proximally and so about 60% of length gained is from the proximal level. During the consolidation phase of treatment, the frame can be dynamized by "decommissioning" the half-pins on the intercalary segment. Pins are decommissioned by removing the cube to which they are attached but leaving the pin itself in situ. This is simpler than actually removing the pins.

### **Bilateral Femoral Lengthening with Correction of Hip Flexion Deformity and Coxa Vara**

Correction of hip flexion contracture is done to help ease the strain on the lumbosacral spine, which is excessively lordotic. Typically, the amount of acute extension at the osteotomy site is about 15 to 20° (Fig. 10A–B). At the same time, it is useful to acutely valgusize the osteotomy in anticipation of some varus that will occur with a monolateral fixator under tension during lengthening (Fig. 11A–B). Precise pin placement is the secret to this procedure. We use the LRS rail system with straight clamps. The upper three pins are placed with the cannulated wire/drill technique at a slope to induce acute apex anterior correction. The middle pin is the pivot point for this correction. Typically, the one to two to four pin holes are used proximally and the one to three to five holes used distally. The distal three pins are placed in the typical pattern, perpendicular to the mechanical axis of the femur, which is not far from the anatomic axis in most patients with dwarfism. Cut the bone just below the lesser trochanter, and acutely translate the upper piece anteriorly and the lower piece posteriorly. Wait five days and begin distraction.

### **Bilateral Humeral Lengthening with and Without Correction of Flexion Deformity**

This is discussed in Chapter 39 on Humeral Lengthening.

### **Lengthening Over Nail/Internal Lengthening Nail**

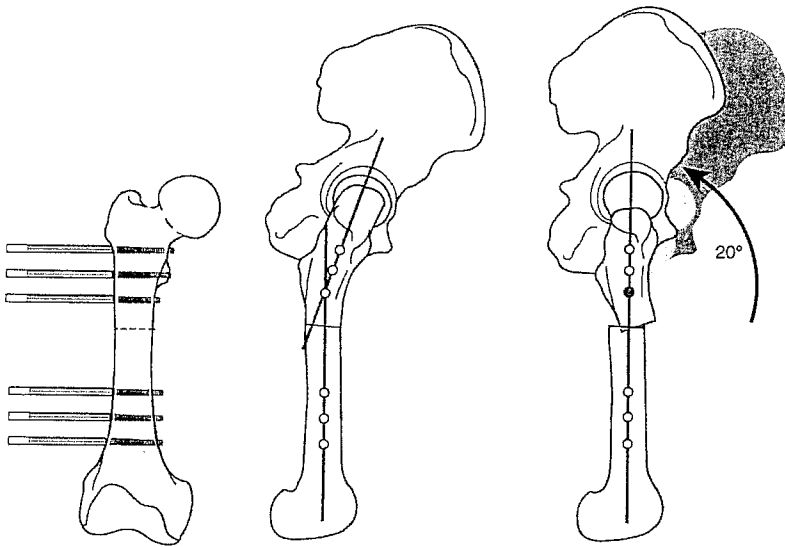
In older adolescents and adults with achondroplasia, it is not unreasonable to consider lengthening over nail (LON) or internal lengthening nail (ILN) methods. These are discussed at length in other chapters in this book. Anatomically, a person with achondroplasia has a short femoral neck, making trochanteric entry safer and easier. This may necessitate the use of a tibial ILN in the femur or a humeral intramedullary nail for LON of the femur (Fig. 12A–C).

## **COMPLICATIONS OF LIMB LENGTHENING FOR ACHONDROPLASIA**

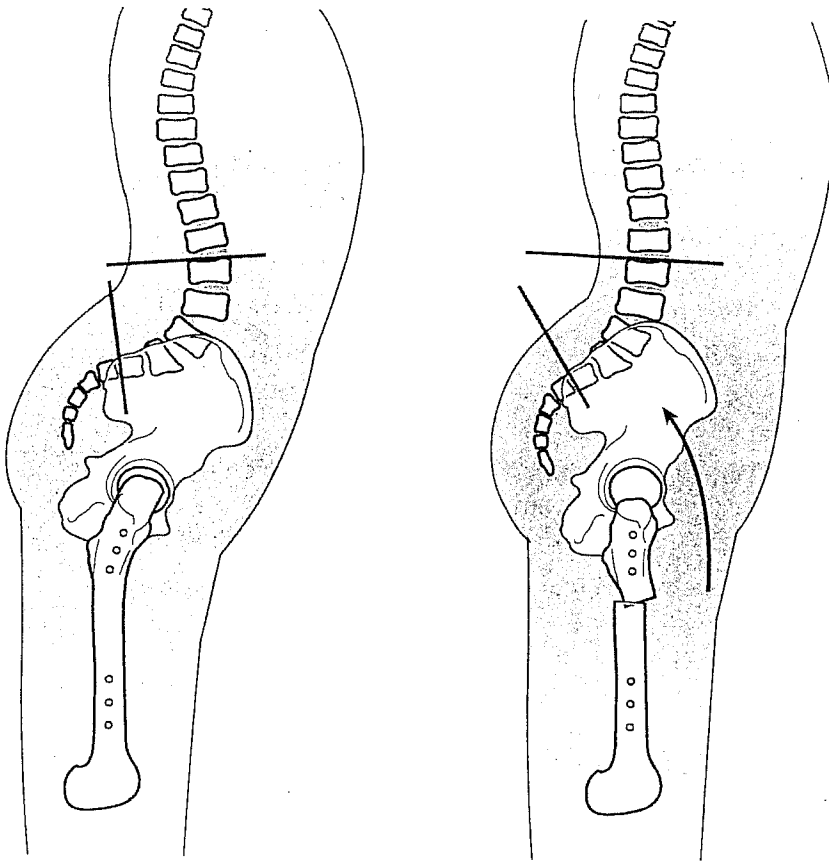
### **Pin Site Infection**

This is the most common minor complication of external fixation treatment. Most pin site infections are superficial presenting with pain and tenderness, redness, and drainage from the pin site. Systemic symptoms such as fever are uncommon. All patients are given a prescription for an oral antibiotic before discharge from the hospital with instructions on self-diagnosis and treatment of pin site infection. This minimizes delay of treatment even if it leads to over-treatment in some cases. If the signs and symptoms subside, the doctor is never notified. If symptoms do not clear, then the patient is instructed to call after 48 hours. At this point, a culture is taken and, if indicated, the antibiotic changed according to the specific sensitivities of the offending organism. If there is any necrotic tissue around the pin site, this is debrided in the office. Prevention of pin infection includes minimizing pin-skin motion especially in the proximal thigh, where there is more ample soft tissue. This can be achieved by dressings that apply direct pressure to the skin. Daily pin care consists of showering with soap daily and drying the pin site with a fresh clean towel. Any crust or scab at the pin site should be picked off with forceps. Cleaning of pins with swabs and saline or peroxide is avoided if the pin site is quiet. This avoids intentionally irritating a nonproblematic pin site. The key to

(A)

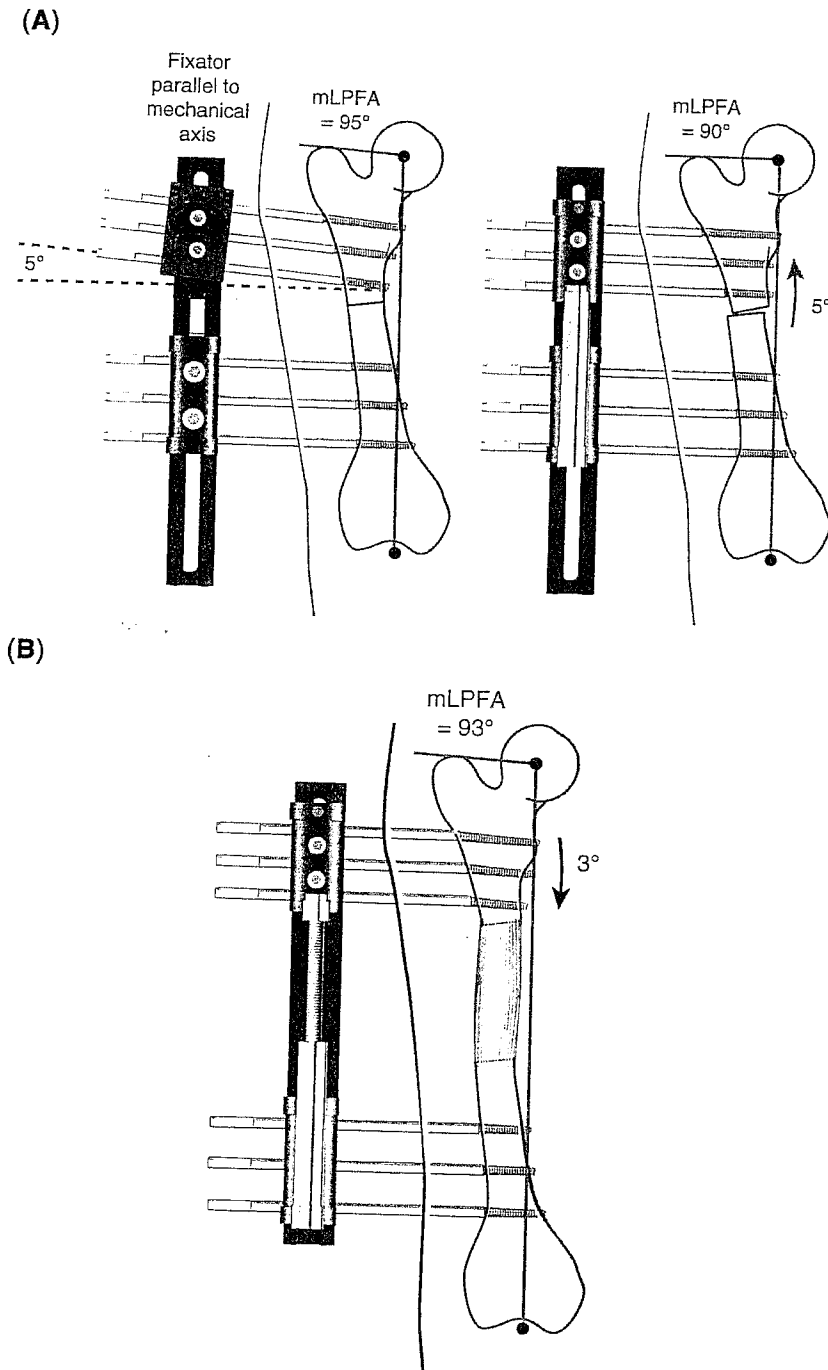


(B)



**Figure 10** (A) The proximal three pins are inserted off axis in the sagittal plane. When the bone is cut and straightened to fit all six pins on the straight monolateral fixator, the proximal femur is extended to create a 20° apex anterior angular osteotomy. (B) The proximal extension osteotomy alleviates the hip flexion contracture and subsequently relieves the lumbar hyperlordosis. The hamstrings will further pull the pelvis into a straighter position during the lengthening, especially if the anterior soft tissues are released as described in Figure 7C.

cleaning the pin sites is as for any wound: removal of any not vital tissue around the pin site and washing the wound with water (shower). When fielding phone calls about pin site infection from patients with fixators, one should always ask pointed questions about the patient's well being. In particular, ask if the child is ill appearing, sickly, glassy eyed, pale, flushed, or



**Figure 11** (A) The proximal three pins are deliberately inserted in about 5° of varus in the frontal plane. Once the bone is cut, the proximal pins are rotated to become parallel with the distal pins and inserted into the straight mono-lateral fixator. This causes an acute 5° of valgus at the osteotomy site. This will likely revert to neutral during lengthening from the force of the pull of the medial muscles. (B) During lengthening, the force of pull of the medial muscles causes the 5° of valgus to return back to the preoperative baseline alignment.

tachycardic. These could be symptoms of a severe, potentially life-threatening infection such as toxic shock or necrotizing fasciitis.

### Nerve Complications

Nerve problems are common during bilateral double-level lengthening of the tibia and less common with single-level lengthening of the tibiae and femora or combined femora and tibiae. It is not clear why the incidence is increased in the double-level group because the nerve

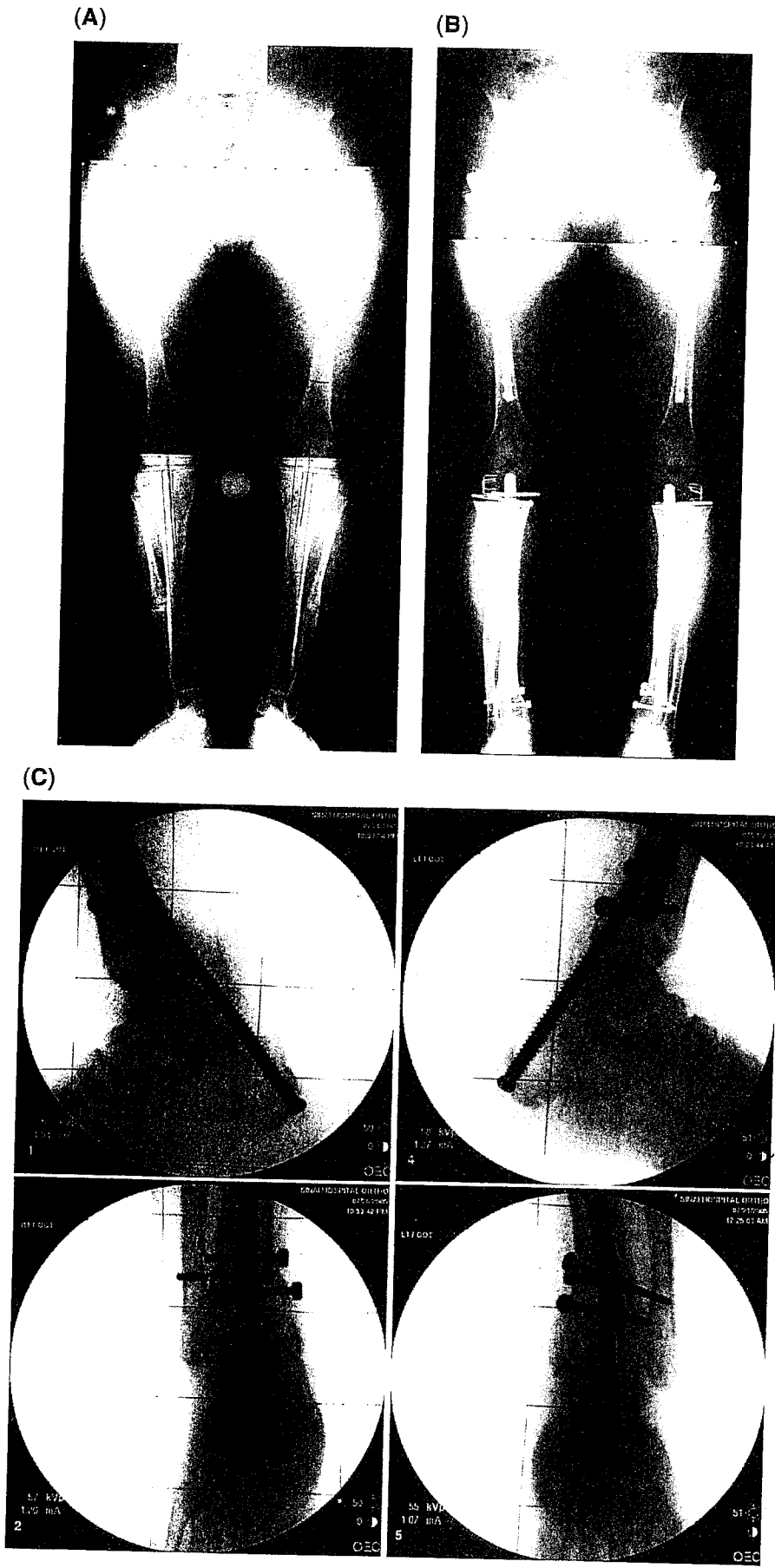


Figure 12 (Caption on facing page)

symptoms appear after an average of only 4 to 5 cm of lengthening. The predisposing factor is probably a small peroneal nerve tunnel. Previous fibulectomy is a predisposing factor. Peroneal nerve problems usually present as referred pain to the foot during tibial lengthening. If left untreated, they would produce a dropfoot. For this reason, it is essential to see the patient every two weeks during the distraction phase. If available, quantitative sensory nerve testing [pressure specified sensory device (PSSD) test] is performed at the time of the follow-up. This allows detection of impending nerve problems even before they are noticed clinically. If they are detected early and the rate of lengthening is slowed, the nerve symptoms may abate and the lengthening can be continued at a slower rate. If despite slowing the lengthening the nerve problem persists, the nerve needs to be surgically decompressed. Decompression should be performed at the level of the neck of the fibula decompressing the nerve at its entry into the common peroneal muscle fascia and the deep peroneal nerve as it passes beneath the intermuscular septum between the lateral and anterior compartments. After the decompression, lengthening is able to continue at the same rate. About 75% of patients undergoing double-level tibial lengthening require this additional procedure. Because it is so common, we consider the nerve decompression as a planned second-stage procedure. Because peroneal nerve entrapment is so common with double-level tibial lengthening, the question has arisen whether prophylactic decompression should be considered. Our preference to date has been to do this as a planned second-stage procedure rather than a prophylactic one. The reason for this is theoretical. We are concerned that if the nerve is decompressed before the onset of symptoms and if referred pain develop we have no remaining options except to stop the lengthening. The advantage of early therapeutic nerve decompression is that it permits the goal of lengthening to be achieved.

### Spinal Cord Injury

Recently, we have become aware of an unusual but serious complication that can occur at the onset, during, or after the lengthening—paraparesis due to spinal cord compromise. We have had three cases of this complication of which two have completely resolved without residual problem and one still has weakness. All three patients had one thing in common—thoracolumbar kyphosis with unrecognized spinal stenosis. Only one had had any previous symptoms of spinal stenosis. In one patient, the problem occurred after the femoral lengthening was completed, in another it occurred during the lengthening, and in the third it occurred on the day of the initial surgery before any lengthening had been performed. We do not think this problem is related to the actual stretch of lengthening but rather to positional injury to the cord that occurred while sitting and sleeping in a wheelchair in a flexed posture for lengthy periods of time or while being transferred to or from the operating room table while under anesthesia. The latter occurred in one case at the time of removal of the fixator and the former at the time of application of the fixators. Both were treated by using a reclining wheelchair for sitting and prone position for sleeping. We now routinely obtain standing long spine radiographs in patients with clinical evidence of thoracolumbar kyphosis as well obtaining magnetic resonance imaging evaluation to assess for spinal stenosis. Patients at high risk in our opinion are sent for a preoperative consultation regarding their spine. Spinal decompression is a surgical option that is considered in a few cases to prevent or treat the spinal stenosis.

### Premature Consolidation

Children with achondroplasia tend to heal regenerate bone faster than normal. Premature consolidation will arrest the lengthening process leading to bending of the pins without increase in length. Premature consolidation that is diagnosed radiographically is treated by lengthening at a faster rate (1.5 mm/day) for a few days. Sometimes this increased tension against resistance will lead to a sudden break through the regenerate bone or through a pin site. This is very painful and causes a sudden separation of the bone ends. If this occurs, it is imperative to diagnose it quickly and to undo any acute diastasis. If not addressed, delayed ossification may result.

**Figure 12** (Figure on facing page) (A) Sixteen-year-old achondroplastic female before lengthening. No malalignment. (B) After bilateral lengthening with Intramedullary Skeletal Kinetic Distractor (ISKD) (Orthofix, McKinney, TX, USA). Femora were lengthened first (5 cm) followed by tibiae (5 cm). (C) Temporary extra-articular screw ankle arthrodesis to prevent equinus during lengthening of tibiae with ISKD.

Fracture through a pin site is also suspected if the patient reports sudden bleeding at the pin site. If premature consolidation is diagnosed, the bone should be reosteotomized at a new level. It is preferable not to osteotomize through the regenerate because consolidation may become delayed.

### Joint Contracture

During combined femoral and tibial lengthening, the emphasis is on knee and ankle ROM, respectively. Daily physical therapy is required. During bilateral double-level tibial lengthening, the feet are held in a 90° position by an extension of the external fixator to prevent contracture. Emphasis at therapy is on walking and knee-extension exercises. During bilateral humeral lengthening, the emphasis is on elbow ROM. During bilateral femoral lengthening, the emphasis is on knee ROM. In addition to formal physical therapy by a trained therapist, the patient is encouraged to exercise at home several times per day. Highly motivated patients recover faster.


Soft-tissue releases are occasionally required during the treatment. These include gastrocnemius-soleus recession when the foot is not included in the fixation. Achilles tendon lengthening should be avoided because it leads to permanent weakness of push off, while recession does not seem to weaken push off. The fascia lata may need to lengthen distally if the knee is developing valgus and flexion. The tensor fascia lata is released proximally to help correct the hip flexion deformity. More extensive release may be required if hip abduction contracture is developing. Recovery of hip, knee, and ankle ROM is predictable. The ankle ROM is the slowest to recover if the gastrocnemius-soleus unit is not lengthened and the foot is not immobilized for the duration of the lengthening to prevent equinus.

### Fracture of Regenerate Bone

Fracture of the bone shortly after frame removal is a problem in lengthening for achondroplasia. Removing bilateral frames exposes both sides to high stress on transfers and weight bearing. In order to reduce the stress, we sometimes remove one side first while simultaneously dynamizing the opposite side (remove some pins), allowing it to strengthen, and then three weeks later remove the frame from the other side. Fractures can occur through the regenerate bone, through pin sites, and through the host-regenerate bone junction. Fractures may also be "silent," i.e., bending but not catastrophic failure. Casting does not reliably prevent postremoval fractures. It is imperative to obtain postremoval radiographs on the day of removal, at about one-week postremoval, and one-month postremoval. Fractures after removal are generally best treated with intramedullary stabilization. In young children, a Rush rod typically is used, and in older adolescents and adults, a locked intramedullary nail is used (Figs. 13,4E). Nailing is challenging because the intramedullary canal is blocked by cortical tracks around old pin sites and the regenerate bone is not yet recanalized. We have found it helpful to use Ilizarov wires and cannulated drills to broach the canal, along with special T-handled reamers of small sizes (3–5 mm) that can be bent to help negotiate curves in the bone. Nailing allows prompt resumption of physiotherapy. The potential risk is infection, due to old pin sites. If the pin sites are not healthy enough to permit nailing, then reapplication of an external fixator is another, though less satisfactory, option.

### Postoperative Management

Clinical follow-up is recommended every 10 to 14 days during the distraction phase. During these visits, radiographs are obtained and sensory nerve testing may be performed in addition to the clinical evaluation by the physician. During the consolidation phase, radiographs are obtained monthly. During one of these visits near the end of the consolidation phase, the external fixator is dynamized. Dynamization is the process of increasing the weight bearing taken by the bone and lessening the load taken by the external fixator. For double-level tibial lengthening, the middle pins are disconnected as part of the dynamization process. The rods or bar of the external fixator are unloaded to allow dissipation of the lengthening forces so that the bone takes more of the weight-bearing load. This helps the bone strengthen and thicken in preparation for removal of the external fixator.



**Figure 13** This female dwarf underwent bilateral simultaneous femoral lengthenings and sustained a fracture of the left femur following removal. This was realigned and held with a Rush Rod. Her tibiae had previously been lengthened and corrected with bilateral double-level lengthenings.

At the end of the distraction phase and before all adjustments are stopped, it is very important to ensure that the bone is straight. Measurements of joint orientation angles are performed on the radiographs to detect axial deviation. If present, the external fixator is adjusted to correct the angles to normal. If this step is skipped, the bone will heal malaligned. We routinely examine for this and correct the joint orientation angles to normal. This is especially important during the double-level tibial lengthening. The other important adjustment that is also made at this stage for tibial lengthening is derotation. An achondroplastic tibia is often internally rotated. Derotation can be facilitated by the TSF. Axial deviation in the femur should be corrected, although adjusting monolateral fixators can be more challenging than circular devices. The Yasui technique can be used to correct frontal plane malalignment provided the pins have been left long enough. Sagittal plane malalignment is somewhat easier to correct with the monolateral multi-axial correcting (MAC) (EBI, Parsippany, NJ, USA) device which can be grafted on top of the Orthofix device if necessary. For these reasons, we generally prefer circular devices for tibial lengthening because axial deviation and correction of deformities are critical (Ilizarov or TSF). In the femur, monolateral fixators are more convenient for the patient.

Bilateral femoral lengthening may be performed by two different methods. If correction of hyperlordosis is important, then formal lengthening is performed with bilateral monolateral

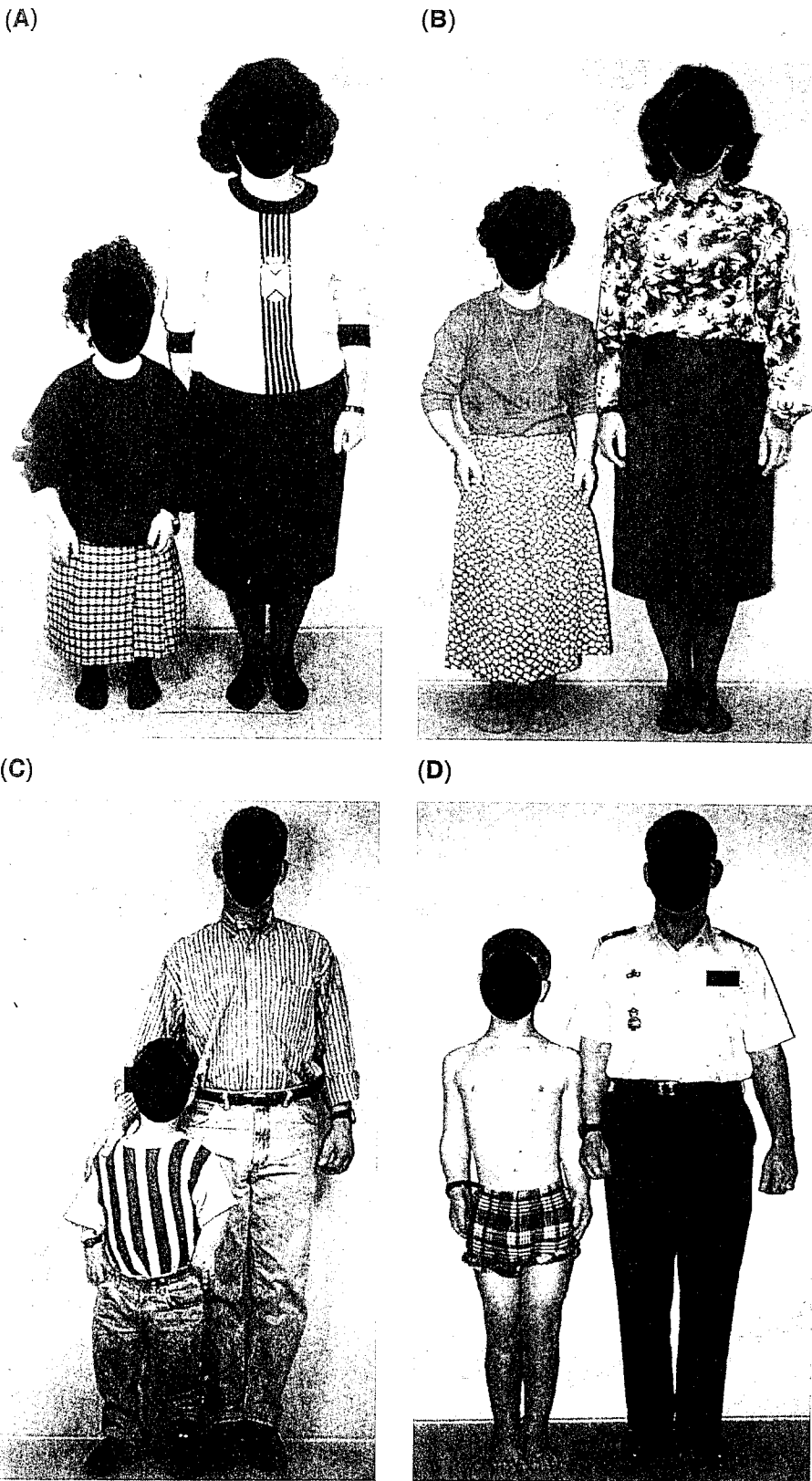
(straight bar) external fixators and extension osteotomy of the proximal femur. If hyperlordosis correction is not required, then LON or intramedullary skeletal kinetic distractor (ISKD) is preferred in the adolescent lengthening, provided the femoral canal can accommodate these devices. LON decreases the time in the fixator by over 50%. For achondroplasia, hyperlordosis and spinal stenosis are important issues. We, therefore, usually prefer to use the fixator-only method so that hyperlordosis is corrected and spinal stenosis is reduced. After six to eight weeks of lengthening, we perform soft-tissue releases of the flexor muscles at the hip to reduce flexion deformity. The external fixator is on for 10 to 12 months followed by a month of bracing following removal. There is usually a stature gain of 2 cm from reduction of lumbar lordosis. This is in addition to the length obtained from lengthening. For hypochondroplasia where hyperlordosis is usually not a problem, LON or, size permitting, fully implantable lengthening with the ISKD are options.

## FUTURE DIRECTIONS AND CONTROVERSIES

Lengthening for stature for dwarfism has been termed extensive limb lengthening (ELL). ELL treatment is controversial in the United States and Canada, but it is a well-accepted part of the management of dwarfism in Europe, Asia, and South America. The interests of patients with dwarfism are represented by the Little People of America (LPA) and Little People of Canada organizations. They have rightfully been wary of such treatments that might lead to serious complications and injury to individuals with dwarfism. This concern dates back to the first experience with lengthening for stature in dwarfism using the Wagner method during the 1970s. Results were complication-ridden with the treatment often being worse than the condition. After several surgical treatments, patients achieved very limited increase in height. With the introduction of the Ilizarov and Orthofix devices to North America in mid-1980s, all this changed. ELL has been more reproducible in some hands. In Baltimore, we use the methods described above, stressing the goal of lengthening to increase the height to the short normal range—5 feet tall in girls and up to 5 feet 4 inches in boys. We also stress correction of deformities while lengthening to improve mechanical axis alignment and joint orientation, reduce the hyperlordosis of the spine, and in some cases, correct the flexion deformity of the elbows. Complications still occur, but they are almost all treatable without leaving permanent sequelae. Long-term results of the European experience and now up to 16-year follow-up on the North American experience have not shown deterioration in results, such as degeneration of joints, muscles, or nerves. In light of these experiences, we feel confident recommending ELL for patients with achondroplasia and hypochondroplasia. We feel that we can safely achieve the goals of treatment in nearly all cases with little to no permanent residual side effects, provided the treatment protocols are strictly followed.

We agree with the LPA that there is no "need" to be lengthened in order to live a productive, healthy life. Similarly, patients with limb-length discrepancy (LLD) do not "need" to undergo limb lengthening. In both situations, the affected individuals can live quite well with special devices to compensate for their disability, e.g., pedal extension so that patients with achondroplasia can use a car and a shoe lift for LLD. Therefore, what are the benefits of ELL that justify the risks and inconvenience of this difficult and lengthy treatment including its multiple planned and unplanned surgeries and extensive rehabilitation?

The benefits from ELL can be divided into functional, psychosocial, and therapeutic. The functional benefits derive from the increased stature and from longer reach. Society has designed the world based on a minimum height of five feet tall. Every day items in our homes, such as door knobs, coat racks, light switches, seat height and depth, toilet seat height, freezer doors, and shower controls, are designed based on a minimum height of 5 feet. The depth of the range and water faucet is based on a certain amount of arm reach. Office environments have copy machines, file drawers, and other surfaces that are out of reach of individuals with dwarfing conditions. Cars have their gas and break pedals out of reach of the short lower limbs. Air bags must be disabled to avoid hitting the short-armed achondroplastic person too strongly in the head because they are holding their head and torso so close to the steering column. Most public telephones are out of reach. By adding a foot of length and increasing height to over 5 feet tall, as well as increasing the reach by 4 inches, all of these items are made easily accessible. Compensatory devices such as stools and stepladders are no longer needed.



**Figure 14** (A,B) Teenager standing next to her mother before and after bilateral tibial lengthening. The increase in height was judged to be satisfactory, and the patient went on to marry. (C,D) Achondroplastic dwarf standing next to his father before and after his first two lengthenings. He subsequently returned for a third lengthening to gain additional height.

Sitting can be easier after leg lengthening, because the feet rest comfortably on the floor rather than dangling.

One of the greatest benefits for achondroplastic patients is humeral lengthening, which has tremendous implications for personal hygiene. As the achondroplastic spine ages, it loses flexibility and it becomes more difficult or even impossible to reach the perineum and carry out personal hygiene.

Psychosocial benefits are also extensive. ELL leads to a complete change in body image. The trunk limb and rhizomelic disproportions are no less pronounced (Fig. 14A–D). Increased height may lead to greater self-confidence and may increase dating options. Increased height may improve job marketability, making more types of employment available.

Finally, ELL has some prophylactic and therapeutic benefits. Reducing the hyperlordosis of the spine should theoretically lead to increased space available to the cord and cauda equina, theoretically reducing the spinal stenosis that is present in all of them. Realignment of the knee should theoretically reduce the likelihood of arthritis, similarly for the ankle and hip. Tightening the lateral collateral ligament makes the knee more stable and eliminates the valgus thrust. Valgusizing the upper femur increases the abduction lever and tension arm leading to less lurch during gait. With the exception of one patient with spinal cord injury, all of our patients said they would undergo this surgery again and that the ordeal was worthwhile because the final result is such a dramatic improvement. Only one patient was made functionally worse with treatment, and now that we better understand the spinal cord problem, paraparesis should be completely avoidable and at least fully recoverable.

The decision to undergo ELL is a personal one and it is not for every family or child. However, we do feel that patients with achondroplasia or hypochondroplasia should be educated about this treatment modality. More studies are needed to document the long-term results and patient outcomes. More centers need to learn these techniques so that patients will not have to travel such long distances to the few centers that offer this treatment. As the technology of lengthening advances with more totally implantable intramedullary lengthening devices, we can expect to see an increased interest in lengthening for dwarfism.

## BIBLIOGRAPHY

- Aldegheri R, Dall'Oca C. Limb lengthening in short stature patients. *J Pediatr Orthop B* 2001; 10(3):238–247.
- Cattaneo R, Villa A, Catagni M, Tentori L, Cassi M. Application of the Ilizarov technic in the lengthening of the humerus. *Rev Chir Orthop Reparatrice Appar Mot* 1986; 72(3):203–209.
- Cattaneo R, Villa A, Catagni M, Tentori L. Limb lengthening in achondroplasia by Ilizarov's method. *Int Orthop* 1988; 12(3):173–179.
- Correll J, Held P. Limb lengthening in dwarfism. *Orthopade* 2000; 29(9):787–794.
- Ganel A, Horoszowski H. Limb lengthening in children with achondroplasia. Differences based on gender. *Clin Orthop Relat Res* 1996; (332):179–183.
- Herzenberg JE, Paley D. Leg lengthening in children [Review]. *Curr Opin Pediatr* 1998; 10(1):95–97.
- Ilizarov GA. Clinical application of the tension-stress effect for limb lengthening [Review]. *Clin Orthop Relat Res* 1990; (250):8–26.
- Kashiwagi N, Suzuki S, Seto Y, Futami T. Bilateral humeral lengthening in achondroplasia. *Clin Orthop Relat Res* 2001; (391):251–257.
- Matsui Y, Yasui N, Kimura T, Tsumaki N, Kawabata H, Ochi T. Genotype phenotype correlation in achondroplasia and hypochondroplasia. *J Bone Joint Surg Br* 1998; 80(6):1052–1056.
- Paley D, Herzenberg JE, Tetsworth K, McKie J, Bhav A. Deformity planning for frontal and sagittal plane corrective osteotomies [Review]. *Orthop Clin North Am* 1994; 25(3):425–465.
- Paley D, Matz AL, Kurland DB, Lamm BM, Herzenberg JE. Multiplier method for prediction of adult height in patients with achondroplasia. *J Pediatr Orthop* 2005; 25(4):539–542.
- Peretti G, Memeo A, Paronzini A, Marzorati S. Staged lengthening in the prevention of dwarfism in achondroplastic children: a preliminary report. *J Pediatr Orthop B* 1995; 4(1):58–64.
- Saleh M, Burton M. Leg lengthening: patient selection and management in achondroplasia. *Orthop Clin North Am* 1991; 22(4):589–599.
- Vilarrubias JM, Ginebreda I, Jimeno E. Lengthening of the lower limbs and correction of lumbar hyperlordosis in achondroplasia. *Clin Orthop Relat Res* 1990; (250):143–149.
- Yasui N, Kawabata H, Kojimoto H, et al. Lengthening of the lower limbs in patients with achondroplasia and hypochondroplasia. *Clin Orthop Relat Res* 1997; (344):298–306.