


REHABILITATION

of the Ilizarov Patient

This technique for limb lengthening, recently brought to the United States, creates special demands and considerations for the rehabilitation team.

BY CAROL FOLKERTS, PT,
SUSAN HENRY, OTR,
HARRY F. KOVELMAN, MD,
PAMELA LENTZ, RN, BSN, ONC,
DROR PALEY, MD, FRCSC, AND
ERIN BOLAND, PT.



Since the recent introduction of the Ilizarov external fixator into North America, many articles have been published regarding its applications, indications, and complications. However, despite all of these articles, physical therapy remains a foundation for all patients in an Ilizarov fixator. To date, there has been no documentation of the techniques employed for a successful physical therapy program.

At the University of Maryland and Mt Washington Pediatric Hospitals, we have treated more than 300 patients with Ilizarov external fixators. In our experience, a successful physical therapy program involves an acute phase, a long-term and/or outpatient phase, and a thorough working knowledge of the problems encountered during limb stabilization. Both bone healing and limb function depend on axial and functional loading of the limb during treatment. Therefore, the PT is an important link in the procedure's success.

BACKGROUND

Limb lengthening and deformity correction by use of external fixation have been documented since 1905.¹ In 1986, a unique fixation system was introduced to the United States and Canada from the Soviet Union. The system was developed in 1951 by Gavriil Ambromovich Ilizarov, MD, in Kurgan.

The original Ilizarov external fixator is a circular device of steel rings, threaded rods, and Kirschner wires. Currently, lightweight carbon fiber rings are also available. The wires are introduced in multiple directions and multiple planes crossing within the bone.² The wires are fixed to the rings and placed under tension. With this frame and bone cuts (osteotomy and/or corticotomy), a bone segment may be lengthened, straightened, rotated, or translated.

In the corticotomy described by Ilizarov, the bone cortex is cut with a 5-mm osteotome. Great care is taken not to enter the medullary cavity in order to spare the nutrient artery and the medullary circulation.³

Approximately seven to ten days follow-

ing surgery, patients turn the threaded nuts .25 mm four times daily. This process pulls the ends of the cut bone attached at either end by the wires at a rate of approximately 1 cm per month. A computerized device can now be programmed to perform the distraction, which allows more turns in smaller increments to be performed, lengthening bones and soft tissues in a way that more closely mimics natural growth processes.⁴

The Ilizarov apparatus allows the patient to bear weight as tolerated within 24 hours of surgery, thus encouraging bone growth and healing. It also avoids multiple surgeries by allowing physicians to modify the apparatus in outpatient settings.

Team members involved in the Ilizarov patient's care may include the patient's family, orthopedic surgeons, nurses, PTs, OTs, psychologists, nutritionists, speech therapists, child life specialists, social workers, and teachers. The patient's disease process, age, body build, hospital course, duration of treatment, personality type, and pain tolerance may influence both surgery and rehabilitation. Patient diagnoses can include fracture, osteomyelitis, nonunion/malunion,

LOWER EXTREMITY EXERCISES

I. Femoral apparatus

A. Isometrics: gluteals, quadriceps, hamstrings.

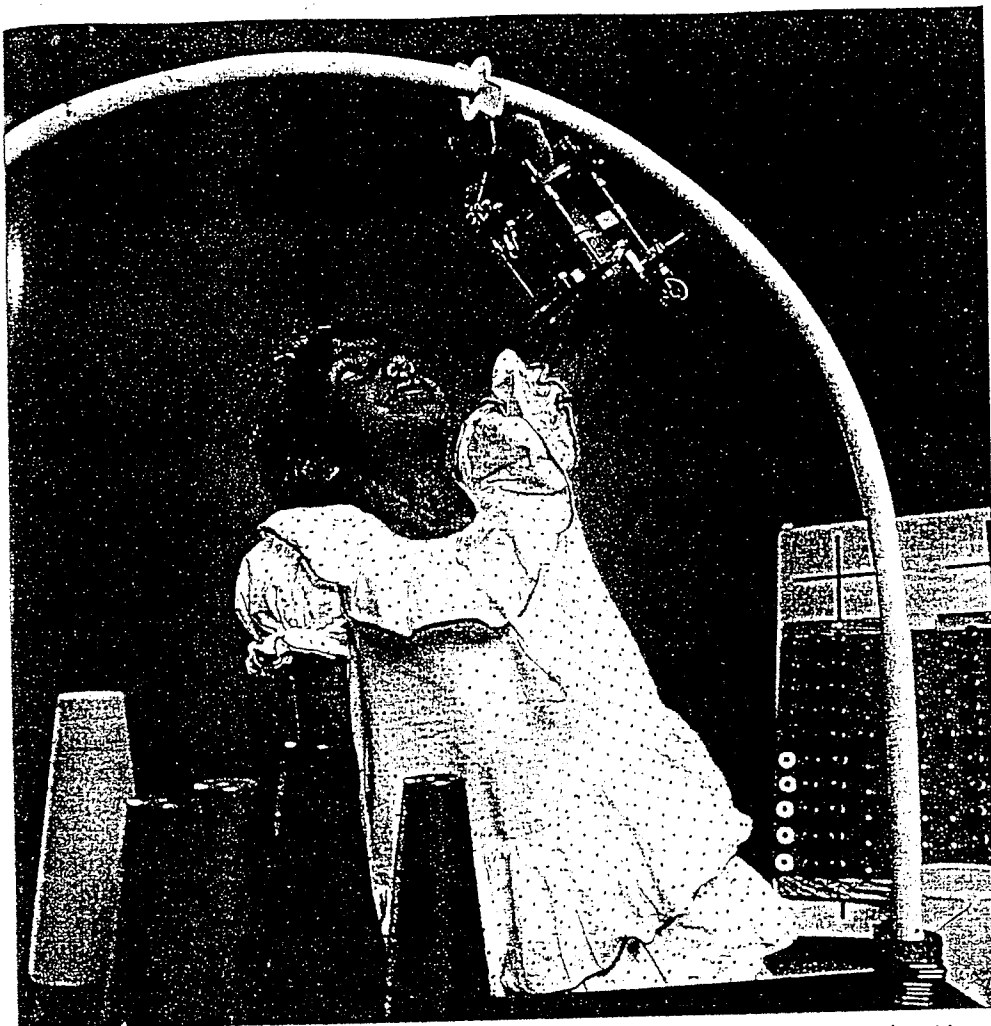
B. Range of motion (prioritized): knee flexion, knee extension, hip abduction, hip extension, hip internal and external rotation, hip flexion.

II. Tibial apparatus

A. Isometrics: quadriceps, hamstrings, tibialis anterior, gastrocnemius soleus.

B. Range of motion (prioritized): ankle dorsiflexion, knee extension, subtalar pronation and supination, toe flexion and extension, ankle plantar flexion, and knee flexion.

TABLE A



Nalini R. Manabhan uses a splint adapted to a forearm frame to maintain her wrist in a neutral position.

limb length discrepancies (posttraumatic and congenital), deformities, contractures, achondroplasia, congenital short stature, polio, avascular necrosis, and hemimelias. Patients may be involved in acute care, long-term, and/or outpatient rehab.

ACUTE REHABILITATION

Preoperative management of patients undergoing the Ilizarov procedure consists of evaluation and initiation of an exercise program that includes gait training. Evaluation includes the patient's medical and surgical history, pain level, goals, range of motion, strength, sensation, limb length discrepancy and/or deformity, posture, coordination, functional status, ambulation skills (for the lower-extremity procedure), fine motor skills (for the upper-extremity procedure), and any other pertinent information. By establishing treatment needs, this evaluation will allow realistic goal-setting by the patient and PT. Plans for frequent postoperative therapy with patient cooperation throughout all stages of the procedure should be emphasized.

Instructions are provided for isometric exercise of muscle groups above, below, and including the region where the fixator is to be applied. A stretching program may be

developed for muscles shortened by the disease process. Patients undergoing the lower-extremity procedure are also instructed in ambulation using a walker or crutches. They will bear weight as tolerated unless otherwise advised by their physicians.

Postoperative hospitalization typically lasts for five to seven days. During this time, patients receive physical therapy twice daily for a total of approximately three hours, five days a week. Physical therapy management begins on the first postoperative day and consists of reevaluation, instruction in and performance of exercises, pain and edema control, splinting, and functional activities, including progressive ambulation. The reevaluation examines physical and behavioral changes that may have occurred since the Ilizarov fixator was applied.

Initial exercises are isometrics and both passive and active assisted range-of-motion work on joints above and below the segment fixed in the apparatus. Active range-of-motion exercises begin as early as the first postoperative day and may include fine motor skills (Tables A and B). Neuromuscular electric stimulation may be used for muscle re-education and facilitation; during femoral lengthening, the quadriceps muscle appears to respond especially well to this.

Goals focus on improving and maintaining strength and motion that were affected by the procedure or previously deficient.

Functional activities are initiated in the hospital, with the patient's level of mobility dictating which activities are appropriate and indicating whether long-term inpatient rehabilitation is necessary. Activities include: bed mobility, transfers, ambulation, unilateral weight bearing, and endurance training. On the first postoperative day, the patient twice stands at the bedside for two to five minutes. The next day, this is increased to three times, and on the third and subsequent days, four times each day.

Gait training starts on the first or second postoperative day. It begins on parallel bars and should progress to a walker or crutches within two to four days. Some patients, especially children, may walk with two quad canes. Even at this early stage, gait deviations are discouraged and appropriate weight shifting is emphasized.

Applications of the Ilizarov apparatus to the leg or to the leg and foot require commercially available or custom-made shoes that aid patients in achieving maximum gait independence. If the patient has no foot deformities and the fixator has not been applied to the foot, a commercially available shoe is used. A custom-molded shoe is needed if the fixator incorporates the foot. Both shoe types should have hook-and-loop tape straps to assist in maintaining normal ankle dorsiflexion. The correct shoe should compensate for the patient's foot deformities and/or leg length discrepancies and

UPPER EXTREMITY EXERCISES

I. Humeral apparatus

A. Isometrics: deltoid, biceps, brachioradialis, triceps.


B. Range of motion (prioritized): elbow extension, elbow flexion, forearm supination and pronation, shoulder abduction, shoulder flexion, shoulder internal and external rotation, shoulder extension and adduction.

II. Forearm apparatus

A. Isometrics: flexor carpi radialis, flexor carpi ulnaris, extensor carpi ulnaris, extensor carpi radialis, pronator tenes supinator.

B. Range of motion (prioritized): finger extension, wrist extension, elbow extension, forearm supination and pronation, finger flexion, wrist flexion, elbow flexion.

TABLE B



Mindy Toby, PT, works on the active range of motion for the knee with Akela Hanif.

The Ilizarov apparatus allows the patient to bear weight as tolerated within 24 hours of surgery, thus encouraging bone growth and healing.

allow him or her to bear weight as normally as possible. As lengthening and deformity corrections occur, the shoe lift can be shaved down and the shoe adjusted.

Before discharge, the patient should be educated and experienced in a home exercise program and in the use of modalities, adaptive shoes, splints, and assistive devices. By discharge, all patients should be independent. However, a majority require further assistance, either from family members and outpatient therapy or from team members at a long-term rehabilitation hospital. Ideally, therapy should continue throughout the period of lengthening and consolidation of bone while the apparatus is applied. After its removal, therapy should continue until range of motion, strength,

and gait have reached their potential.

LONG-TERM REHABILITATION

Long-term rehabilitation may be completed on an inpatient or outpatient basis. An inpatient stay is recommended for patients with compromised social situations, combination lengthenings, poor functional mobility, or residence too far from the rehabilitation facility to allow frequent visits. Typically, pediatric patients with combination lengthenings are seen as inpatients. Inpatient rehabilitation consists of one hour of hydrotherapy and two hours of therapeutic exercise, functional activities, and gait training, five days a week.

Frequency of outpatient rehabilitation can vary. Outpatients at Mt Washington Pediatric Hospital receive the same therapy program as inpatients, but most outpatient clinics are not designed to accommodate such demanding frequencies. In these situations, outpatients receive one to two hours of treatment, three to five times a week, and complete a home exercise program of one to two hours per day. Goals of the physical therapy program are to improve passive range of motion, prevent contracture formation, improve or maintain strength, maximize mobility, and increase functional independence. Specific objectives are established for each patient after evaluation.

Exercises are designed to maximize strength and range of motion. Table A lists the muscles and joint motions for each lower-extremity limb segment. Functional activities are designed to increase independence, as well as to improve strength and coordination. Endurance training is incorporated through the use of bicycles and treadmills.

Balance and coordination are addressed throughout the therapy program. Patients undergoing this procedure are typically unable to bear weight effectively due to the surgical procedure or to pain from the lengthening process. Gait quality is compromised by lack of proprioceptive input and insufficient weight bearing. The joints and muscles of the ankle should be rehabilitated in the weight-bearing position to stimulate proper function.⁵ To facilitate acquisition of balance skills, activities should include weight shifting in standing and balance activities. By stressing balance and coordination activities, the patient can steadily improve gait quality, thereby reducing the intensity of therapy when the apparatus is removed.

Pool therapy is an integral part of the rehabilitation process. Patients can begin in the pool ten to 14 days after surgery. Flotation

devices are used to provide resistance or support. Utilizing various depths of water can challenge balance coordination and weight bearing. A styrofoam shoe lift may be needed if the affected lower extremity does not reach the weight-bearing surface.

Patients with upper-extremity lengthenings do not qualify for long-term inpatient rehabilitation due to their level of function. Insurance coverage typically allows for long-term outpatient treatment. At Kernan Hospital, patients are treated daily for one to 1 ½ hours. Exercises for range of motion and strength are performed (Table B). Upper-extremity patients also get whirlpool therapy to assist with pin-site care and range of motion. Peg and hook-and-loop tape boards, finger exercises, and clothespins can be used to promote fine motor coordination and pinch strength. Therapeutic putty and band-resistance exercises can be incorporated into home treatment.

PROBLEMS

Problems encountered during treatment have included contractures, pain, edema, nerve damage, and pin-site problems.⁶ The team must work together to prevent these. The therapist should be alert for patient or family noncompliance, especially in splint use or exercise. Shoe-lift height should be monitored during the lengthening period. If the involved extremity is over-lengthened, the uninvolved extremity should be fitted for a shoe lift.

CONTRACTURES

Pin-site infections excepted, contractures are the most frequent complication of the Ilizarov procedure. Therefore, contracture prophylaxis is an essential part of treatment in a limb-lengthening procedure. Contracture etiology can be nonsurgical or surgical. In the former case, tension is generated in peripheral nerves and muscles when the bone is distracted. To overcome this stress, the muscles flex or extend adjacent joints.

When lengthening the tibia, for example, the gastrocnemius soleus muscles tend to flex the knee and plantarflex the ankle as they become tighter. To prevent this, the foot should be dorsiflexed maximally with the knee in flexion. Then, with the ankle held in dorsiflexion, the knee should be extended passively.

In femoral lengthenings, the knee is susceptible to joint subluxation because of its inherent lack of bony stability.⁷ When the knee is flexed, the hamstring muscles can work unopposed to pull the tibia posteriorly

on the femoral condyles. If the knee is maintained in extension, the proximal pull of the hamstrings is resisted by axial alignment of the tibia on the femur.

As the bone lengthens, muscle length may remain relatively unchanged. If muscle length does not increase proportionately, the joints involved will lose motion. Initially, this limitation involves only muscle and neurovascular structures, but it may eventually involve the joint capsule.

Surgical causes of contracture occur during placement of wires through bone, muscles, fascia, and tendons. Careful placement of wires during surgery will produce better range of motion, reduced pain, and longer periods of weight bearing.

Contracture prophylaxis is a necessity. To date, primary preventive measures have included stretching and functional exercises during physical therapy, splinting, external fixation across joints, and fascial and tendon lengthening or release. Splinting begins in the hospital and continues throughout the lengthening phase. If contractures occur, splints are also used during the consolidation phase and after apparatus removal. Ankle dorsiflexion is assisted by a shoe worn with tension on its dorsiflexion straps or by the use of an ankle splint with knee extension. A similar splint assists in elbow extension. A typical wearing schedule consists of a minimum of six to eight hours of wear at night.

The principle of avoiding contractures is to place the muscle under tension for as many hours as possible. It has been shown that stretching exercises do not prevent contractures unless they can be maintained for at least six hours per day.^{8,9}

Control of edema and pain should be addressed by all team members. The PT's role includes monitoring problems and educating patients in positional techniques and the use of modalities. Upper and lower extremities need to be elevated above heart level (the knee remains in full extension) for edema control at all times, except during therapy. Both edema and pain can be decreased using ice. When pain without edema is present, heat may also be used.

Electrostimulation can be used alone, or in conjunction with ice or heat, for pain control. Physicians may also prescribe acetaminophen with codeine, nonsteroidal anti-inflammatory drugs, oxycodone, or analgesic pumps. Edema and pain must be limited if the goals of therapy are to be achieved.

During the Ilizarov procedure, nerve

damage can occur either secondary to placement of a wire on or near a nerve, or it can be related to the distraction process itself. The therapist's goal should be to recognize early signs and symptoms of neurologic compromise, usually hyperesthesia and pain followed by hypoesthesia, decreased muscle strength, and paralysis.⁶ At the first sign of neurologic compromise, the surgeon should be notified immediately.


CONCLUSION

Rehabilitation is an ongoing process for patients undergoing the Ilizarov technique. Constant monitoring to avoid problems is essential. Patients and their therapists develop a trusting relationship and can work together until strength, motion, and function are restored. Conventional exercises, modalities, and pool therapy can all be incorporated into the patient's program. Continued efforts to gain knowledge from team members' experiences will result in positive outcomes, now and in the future. □

Carol Folkerts, PT, is on staff in the Department of Physical Therapy; Harry F. Kovelman, MD, is a clinical assistant, Division of Orthopedics, Ilizarov Team; Pamela Lentz, RN, BSN, ONC, is nurse coordinator, Department of Surgery, Ilizarov Team; and Dror Paley, MD, FRCSC, is an assistant professor, Department of Surgery, Division of Orthopedics at University of Maryland Hospital, Baltimore. Susan Henry, OTR, is on staff in the Department of Occupational Therapy, Kernan Hospital, Baltimore. Erin Boland, PT, is on staff in the Department of Physical Therapy, Mt Washington Pediatric Hospital, Baltimore.

REFERENCES

1. Codivilla A. On the means of lengthenings in the lower limbs, the muscles, and tissues which are shortened through deformity. *Am J Orthopaedic Surg.* 1905;2:353-end page.
2. Fleming B, Paley D, Kristiansen T, Pope M. A biomechanical analysis of the Ilizarov external fixator. *Clin Ortho Rel Res.* 1989;241:95-105.
3. Paley D. Current techniques of limb lengthening. *J Pediatr Ortho.* 1988;8:73-92.
4. Ilizarov GA. The tension-stress effect on the genesis and growth of tissues: Part II. The influence of the rate and frequency of distraction. *Clin Ortho Rel Res.* 1989;239:263-285.
5. Garn SN, Newton RA. Kinesthetic awareness in subjects with multiple ankle sprains.



Erin Boland, PT, helps Latonya Smallwood with gait training in the parallel bars.

Before discharge, the patient should be educated and experienced in a home exercise program and in the use of modalities, adaptive shoes, splints, and assistive devices—

Phys Ther. 1988;68:1669-end page.

6. Paley D. Problems, obstacles, and complications of limb lengthening by the Ilizarov technique. *Clin Ortho Rel Res.* 1990;250:81-104.

7. Jones DC, Moseley CF. Subluxation of the knee as a complication of femoral lengthening by the Wagner technique. *J Bone Joint Surg.* 1985;67:33-end page.

8. Tardieu C, Lespargot A, Tabary C, Bret MD. For how long must the soleus muscle be stretched each day to prevent contracture? *Devel Med Child Neurol.* 1988;30:3-10.

9. Ziv I, Blackburn N, Rang M, Korerska J. Muscle growth in normal and spastic mice. *Devel Med Child Neurol.* 1984;26:94-99.