



ELSEVIER

# Prophylactic and Therapeutic Peroneal Nerve Decompression for Deformity Correction and Lengthening

Monica Paschoal Nogueira, MD,<sup>\*,†,‡</sup> and Dror Paley, MD, FRCSC<sup>§</sup>

**Nerve injury is one of the most serious and frequent complications of deformity correction and limb lengthening. Acute or gradual deformity correction or limb lengthening is frequently complicated by nerve injury. The peroneal nerve is the most frequently injured around the knee and the upper tibia. Decompression of this nerve should be considered as prophylactic and therapeutic treatment to avoid injury and ensure recovery, respectively. There are 2 tunnels of entrapment near the neck of the fibula. Knowledge of this anatomy is important to all surgeons treating patients at risk of this injury.**

**Oper Tech Orthop 21:180-183 © 2011 Elsevier Inc. All rights reserved.**

**KEYWORDS** entrapment, nerve decompression, peroneal nerve

Peroneal nerve entrapment and injury are well-known complications of trauma, acute deformity correction, and of limb lengthening.<sup>1-12</sup> The primary entrapment described is at the neck of the fibula. Peroneal nerve decompression is a well-recognized technique for the treatment of peroneal nerve palsy and entrapment.<sup>7,13</sup> For prophylactic use, the indication for peroneal nerve decompression is a nerve at risk (eg, acute valgus correction of tibia of more than 5°, acute valgus correction of the femur of more than 5°). Mont et al<sup>7</sup> reported that correction of deformities of more than 15° of valgus put the nerve at risk when performing total knee arthroplasty and achieving correction in varus.

For therapeutic decompression, the indication is when there are signs or symptoms of nerve problems (eg, referred pain to the dorsum of foot, hypersensitivity or hyposensitivity, weakness or paralysis of muscles). The potential complications of nerve decompression are nerve injury, infection, and hematoma.

Nogueira et al<sup>14</sup> found that peroneal nerve decompression is efficacious for the treatment of peroneal nerve injury secondary to acute and gradual deformity correction and lengthening.

Nerve stretch injuries are caused when distraction overcomes the nerve-fibers' elastic and plastic properties. These injuries have been the subject of many studies.<sup>15-17</sup> It has been assumed that nerve injury resulting from limb lengthening and from acute valgus to varus deformity correction is a stretch injury.

When nerve decompression was performed on patients undergoing limb lengthening, intraoperative findings included hemorrhage, nerve flattening, narrowing of the nerve at the entrance of the fascial tunnel, and reduction of the perineural vascularization at the site of compression,<sup>14</sup> findings typical of nerve entrapment and not stretch injury.<sup>14</sup>

Nogueira, et al<sup>14</sup> documented that when peroneal nerve injuries are caused by limb lengthening, acute deformity correction, or gradual deformity correction, the timing of decompression affected the rate of nerve recovery. Performing an early decompression resulted in patients experiencing an early recovery, and performing a late decompression resulted in patients experiencing a late recovery.<sup>14</sup> However, the authors failed to find a relationship between nerve injury and the amount or percent of lengthening, suggesting again that entrapment and not stretch injury is the cause.

Nerve entrapment might also be a factor when stretch, acute trauma, or compression injury occurs. Injury leads to inflammation. The peroneal tunnels are normally very tight,

\*Hospital do Servidor Público Estadual, São Paulo, SP, Brazil.

†Hospital da Beneficência Portuguesa, São Paulo, SP, Brazil.

‡AACD, Associação de Assistência à Criança Deficiente, São Paulo, SP, Brazil.

§Paley Advanced Limb Lengthening Institute, St. Mary's Medical Center, West Palm Beach, FL.

Address correspondence to Monica Paschoal Nogueira, MD, Hospital do Servidor Público Estadual, Hosp da Beneficência Portuguesa, AACD, Associação de Assistência à Criança Deficiente, São Paulo, SP, Brazil.  
E-mail: monipn@uol.com.br

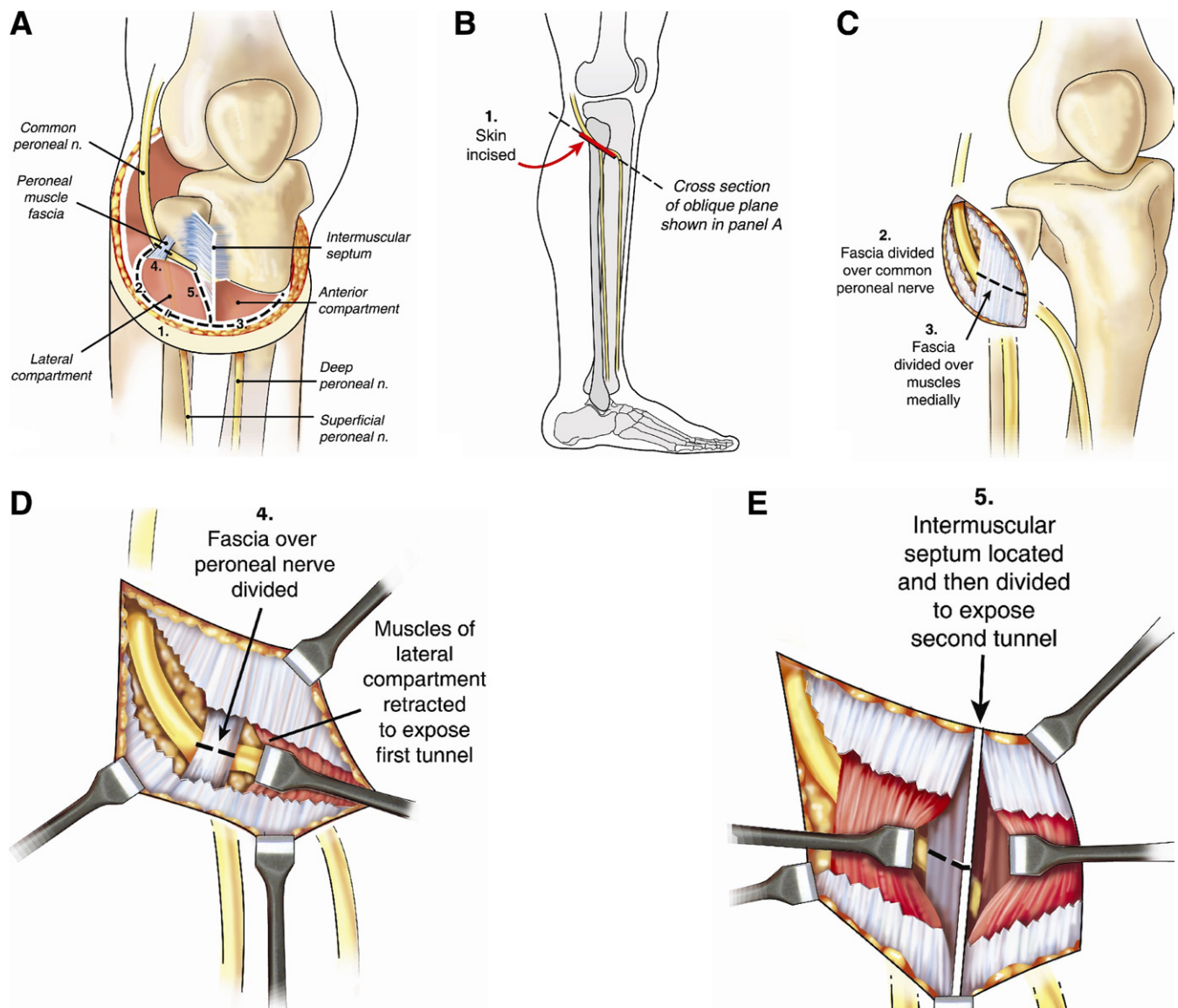
leaving little space to accommodate additional swelling. Consequently, a secondary injury might follow the original stretch injury when the nerve swells against the nonexpandable walls of the peroneal tunnels.

Therefore, early decompression is warranted while the initial injury is recoverable; the secondary injury might make the situation irrecoverable. This is suggested by the observation that the longer the interval between the injury and the decompression, the longer the interval until recovery of the nerve.<sup>14</sup>

Prophylactic or therapeutic decompression is the standard of care for the median nerve of the hand. The carpal tunnel is

much more capacious than the peroneal tunnels. Prophylactic or therapeutic nerve decompression within 24 hours should also become the standard of care for the peroneal nerve.

If tension can precipitate entrapment, then decompression should be able to reduce the tension on the peroneal nerve. Paley<sup>18</sup> identified 2 sites of entrapment and described a surgical technique to decompress both tunnels (Fig. 1A-E). Nogueira demonstrated in a cadaver study that both tunnels described by Paley are important points of entrapment of the peroneal nerve, and that the nerve tension which increases



**Figure 1** Paley's technique<sup>11</sup> of 2-tunnel peroneal nerve decompression is shown. (A) The peroneal nerve passes through 2 potential entrapment tunnels: the peroneal fascia and the intermuscular septum. (B) Short oblique skin incision is made in the same direction as the nerve (step 1). (C) Superficial peroneal fascia is divided outside of the peroneal muscles (steps 2 and 3), and the common peroneal nerve is identified. (D) Peroneal muscle fascia is cut. The underlying peroneal muscles are retracted medially exposing the deep peroneal muscle fascia, which is then divided (Step 4). (E) Transverse fascial incision is extended towards the tibia crossing the intermuscular septum between the anterior and lateral compartments of the leg. The muscle on either side is retracted, and the septum is transected under direct vision (Step 5). The deep peroneal nerve passes under this septum but is not visualized (Source: Limb Lengthening and Reconstruction S. Robert Rozbruch).

after varus osteotomy, decreases to normal levels after peroneal nerve decompression.<sup>19</sup>

The first peroneal nerve tunnel is located at the neck of the fibula. The common peroneal nerve leaves the undersurface of the biceps muscle to enter the lateral compartment of the leg. To enter the lateral compartment the common peroneal nerve must perforate the otherwise intact fascial coverings of this compartment. The lateral compartment fascia folds over itself to form an arcade over the common peroneal nerve.

The common peroneal nerve then splits into its superficial and deep branches. The superficial peroneal nerve continues unimpeded through the lateral compartment innervating the peroneal muscles. The deep branch has to pass under the intermuscular septum (second peroneal nerve tunnel) to enter the anterior compartment of the leg. The intermuscular septum separates the anterior from the lateral compartment. Anteriorly it is confluent with the lateral and anterior compartment fascia. Posteriorly it abuts but does not become part of the interosseous membrane. The deep peroneal nerve passes between the interosseous membrane and the intermuscular septum. The septum when tensioned is like a sharp fascial edge resting on the deep peroneal nerve. It is no wonder that anything that leads to tension of the septum will entrap the deep peroneal nerve separate from the common or superficial branches.

## Surgical Technique for Decompression of the Peroneal Nerves

This surgery can be performed with or without a tourniquet but without long-acting neuromuscular blockade (Fig. 1). The patient is positioned supine, with a bump under the ipsilateral buttock. The common peroneal nerve can be palpated in most people over the neck of the fibula. To palpate the nerve, roll it with the thumb or finger over the neck of the fibula. Make a 3- to 5-cm oblique incision parallel to the course of the nerve over the neck of the fibula. Cut through skin and subcutaneous tissues down to the fascia posterior to the lateral compartment. Feel for the nerve again with the skin open. Once the nerve has been identified, cut over the nerve and identify its proximal and distal borders. It is not necessary to remove the fat over the nerve. Follow the common peroneal nerve until it disappears into the lateral compartment. Do not attempt to decompress the nerve yet. Make a transverse incision over the lateral compartment fascia and expose the muscle of the lateral compartment. Retract the muscle of the lateral compartment medially to expose the underlying arcade of fascia covering the common peroneal nerve. This is the decompression of the first tunnel. The common peroneal nerve can be seen dividing into deep and superficial branches, the superficial running down in the lateral compartment, and the deep branch going in the direction of the anterior compartment of the leg.

Extend the transverse compartment fasciotomy across to the anterior compartment. Notice the intermuscular septum separating the 2 compartments and confluent with the fascia

overlying both compartments. Dissect the muscle off both sides of the septum. Be careful not to cut any superficial sensory branches of the nerve that may ascend the septum and innervate the skin overlying the compartments. With the septum exposed on its medial and lateral aspects cut it from anteromedial to posterolateral. Be careful to stop as soon as the septum ends. Immediately below the septum a band of fat can often be seen. This fat band contains the deep peroneal nerve. This completes the decompression of the deep peroneal nerve (second tunnel).

If a tourniquet was used it should be let down at this point. The nerve can be stimulated with a disposable nerve stimulator. If the tourniquet time exceeds 20 minutes the nerve may not respond to electrical stimulation initially as the result of tourniquet ischemia. If the nerve was paralyzed before decompression, it can be stimulated before the decompression at the common peroneal nerve and then again after the decompression.

## Discussion

Nerve stretch injuries are caused when distraction overcomes the nerve fibers' elastic and plastic properties. These injuries have been the subject of many studies.<sup>15-17</sup> It has been assumed that nerve injury resulting from limb lengthening and from acute valgus to varus deformity correction is a stretch injury.

When nerve decompression was performed on patients undergoing limb lengthening, intraoperative findings included hemorrhage, nerve flattening, narrowing of the nerve at the entrance of the fascial tunnel, and reduction of the perineural vascularization at the site of compression,<sup>14</sup> findings typical of nerve entrapment and not of stretch injury.<sup>14</sup>

Nogueira et al<sup>14</sup> used peroneal nerve decompression both prophylactically and therapeutically when performing acute valgus to varus deformity corrections about the knee. Intraoperative potential nerve monitoring was used in some cases, and a sudden loss of nerve potentials was observed minutes after acute valgus to varus correction.<sup>14</sup> Immediate decompression of the nerve leads to restoration of normal potentials.<sup>14</sup> The report of Nogueira et al<sup>14</sup> has suggested that the problem may be one of nerve entrapment instead of stretch injury.

Nerve entrapment might also be a factor when stretch, acute trauma, or compression injury occurs. Injury leads to inflammation. The peroneal tunnels are normally very tight, leaving little space to accommodate additional swelling. Consequently, a secondary injury (double crush) might follow the original stretch injury when the nerve swells against the nonexpandable walls of the peroneal tunnels.

Therefore, early decompression is warranted while the initial injury is recoverable; the secondary injury might make the situation irrecoverable. This is suggested by the observation that the longer the interval between the injury and the decompression, the longer the interval until recovery of the nerve.<sup>7,14</sup>

These authors recommend prophylactic decompression when the nerve is at risk for stretch or entrapment as the

result of acute deformity correction of valgus or flexion of the proximal tibia, distal femur and knee. The authors recommend therapeutic decompression of the peroneal nerve as soon as possible (preferably within 24 h) after a peroneal nerve injury from any cause (eg, surgery, trauma, compression). The peroneal nerve should be treated with the same rules as apply to the median nerve.

## References

1. Atar D, Lehman WB, Grant AD, et al: Treatment of complex limb deformities in children with the Ilizarov technique. *Orthopedics* 14: 961-967, 1991
2. Coleman SS: Simultaneous femoral and tibial lengthening for limb length discrepancies. *Arch Orthop Trauma Surg* 103:359-366, 1985
3. Coleman SS, Stevens PM: Tibial lengthening. *Clin Orthop Relat Res* 136:92-104, 1978
4. Dahl MT, Gulli B, Berg T: Complications of limb lengthening: A learning curve. *Clin Orthop Relat Res* 301:10-18, 1994
5. Eldridge JC, Bell DF: Problems with substantial limb lengthening. *Orthop Clin North Am* 22:625-631, 1991
6. Galardi G, Comi G, Lozza L, et al: Peripheral nerve damage during limb lengthening. Neurophysiology in five cases of bilateral tibial lengthening. *J Bone Joint Surg Br* 72:121-124, 1990
7. Mont MA, Dellon AL, Chen F, et al: The operative treatment of peroneal nerve palsy. *J Bone Joint Surg Am* 78:863-869, 1996
8. Noonan KJ, Price CT, Sproul JT, et al: Acute correction and distraction osteogenesis for the malaligned and shortened lower extremity. *J Pediatr Orthop* 18:178-186, 1998
9. Paley D: Problems, obstacles, and complications of limb lengthening by the Ilizarov technique. *Clin Orthop Relat Res* 250:81-104, 1990
10. Rose HA, Hood RW, Otis JC, et al: Peroneal-nerve palsy following total knee arthroplasty. A review of The Hospital for Special Surgery experience. *J Bone Joint Surg Am* 64:347-351, 1982
11. Strong M, Hruska J, Czyrny J, et al: Nerve palsy during femoral lengthening: MRI, electrical, and histologic findings in the central and peripheral nervous systems—a canine model. *J Pediatr Orthop* 14:347-351, 1994
12. Velazquez RJ, Bell DF, Armstrong PF, et al: Complications of use of the Ilizarov technique in the correction of limb deformities in children. *J Bone Joint Surg Am* 75:1148-1156, 1993
13. Humphreys DB, Novak CB, Mackinnon SE: Patient outcome after common peroneal nerve decompression. *J Neurosurg* 107:314-318, 2007
14. Nogueira MP, Paley D, Bhava A, et al: Nerve lesions associated with limb-lengthening. *J Bone Joint Surg Am* 85-A:1502-1510, 2003
15. Chuang TY, Chan RC, Chin LS, et al: Neuromuscular injury during limb lengthening: A longitudinal follow-up by rabbit tibial model. *Arch Phys Med Rehabil* 76:467-470, 1995
16. Wall EJ, Massie JB, Kwan MK, et al: Neuropathy: Changes in nerve conduction under tension. *J Bone Joint Surg Br* 74:126-129, 1992
17. Young NL, Davis RJ, Bell DF, et al: Electromyographic and nerve conduction changes after tibial lengthening by the Ilizarov method. *J Pediatr Orthop* 13:473-477, 1993
18. Paley D: Principles of Deformity Correction. 1st ed, Corr. 3rd 15 printing. Rev ed. Berlin, Springer-Verlag, 2005
19. Nogueira MP, Pereira CAM, Hernandez AJ, et al: Biomechanical Study of the Tension of the Fibular Nerve and the Importance of Its Surgical Decompression in Lower Limb Deformity Correction—A Cadaver Study. *Limb Lengthening and Reconstruction Society Association for the Study and Application of the Methods of Ilizarov North America. The Fairmont Coply Plaza Hotel. Boston, MA*